

Dermoscopy in Hair Disorders (Trichoscopy)

Dr Rajendra C. Shinde

Professor & Head

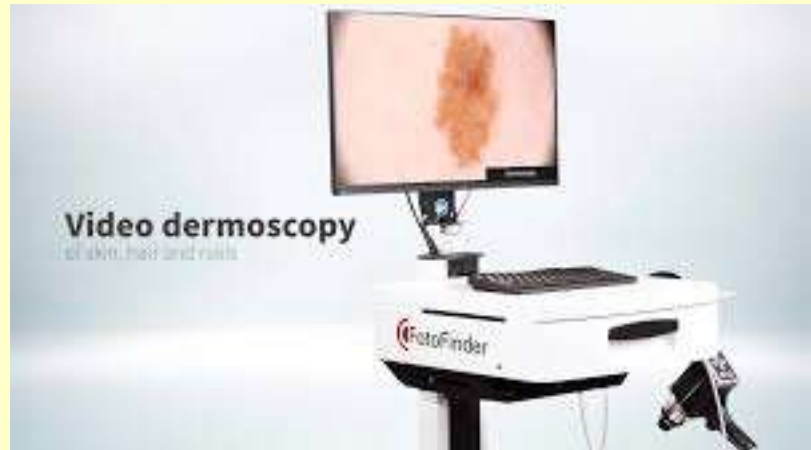
Mimer medical College

Talegaon Dabhade, Pune

Introduction

- Hair fall is the most common complaint
- Trichoscopy is dermoscopy of hair and scalp (Lidia Rudnicka & Malgorzata olszewska)
- Simple, noninvasive very handy bedside tool with easy to achieve expertise

Instruments

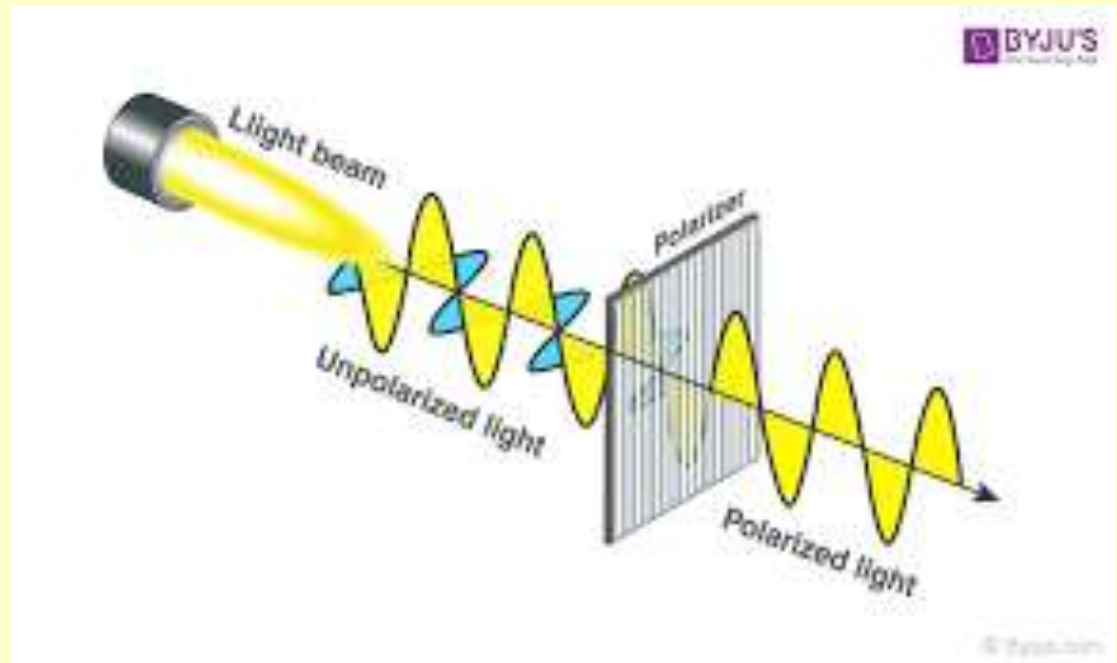


Polarized vs non polarized (vascular and pigmentation)



Without polarised lens

With polarised lens

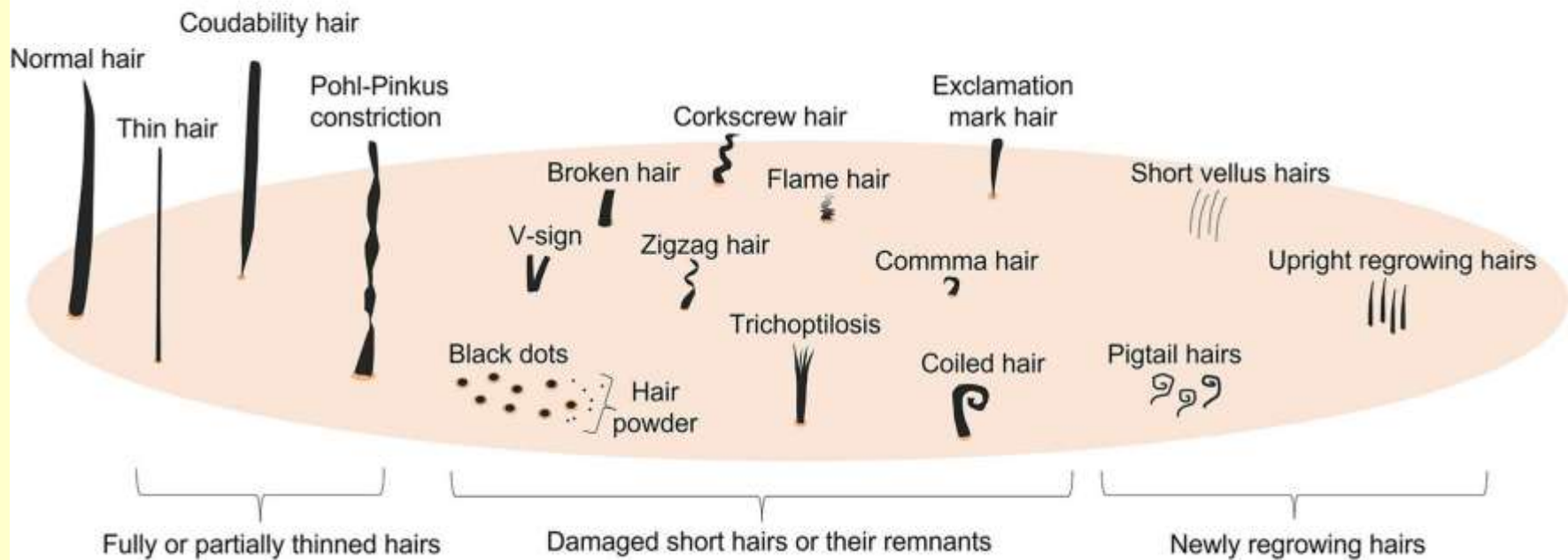


What to look for ?

- Hair shaft
- Follicular openings (dots)
- Interfollicular skin esp. scaling
- Blood vessels

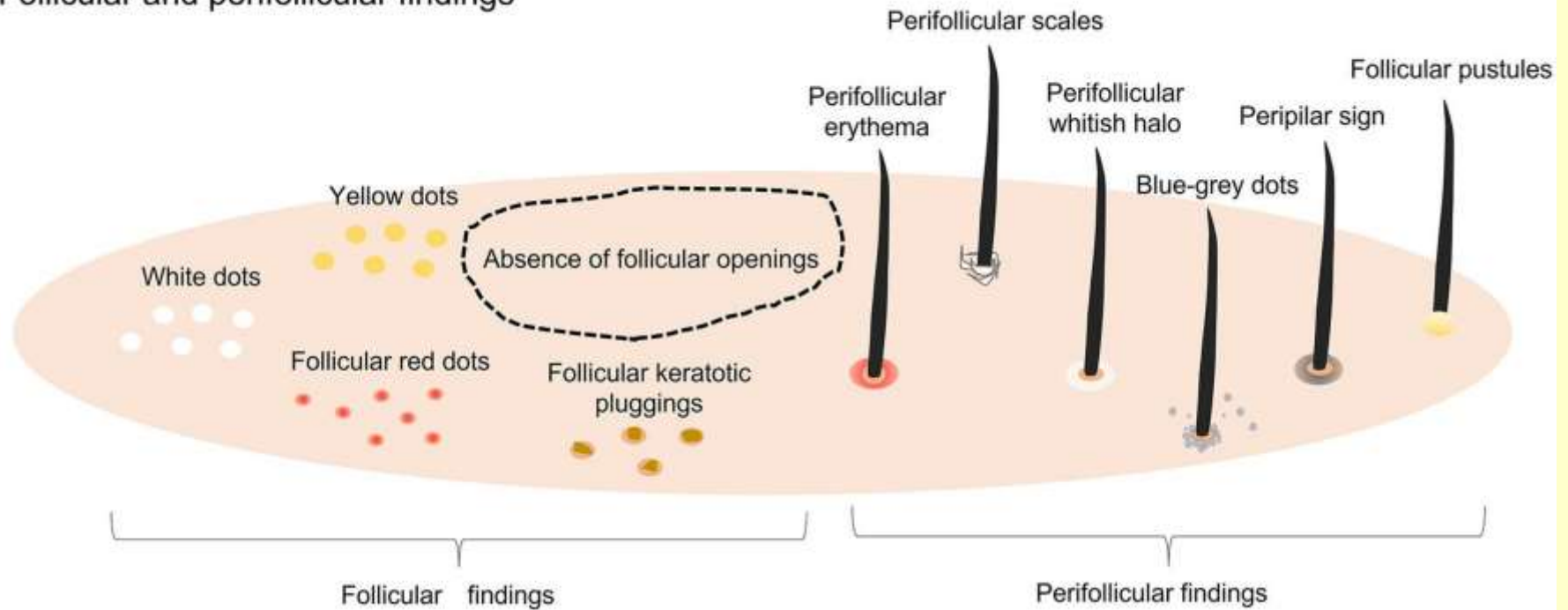
Hair Shaft findings

Hair shaft findings



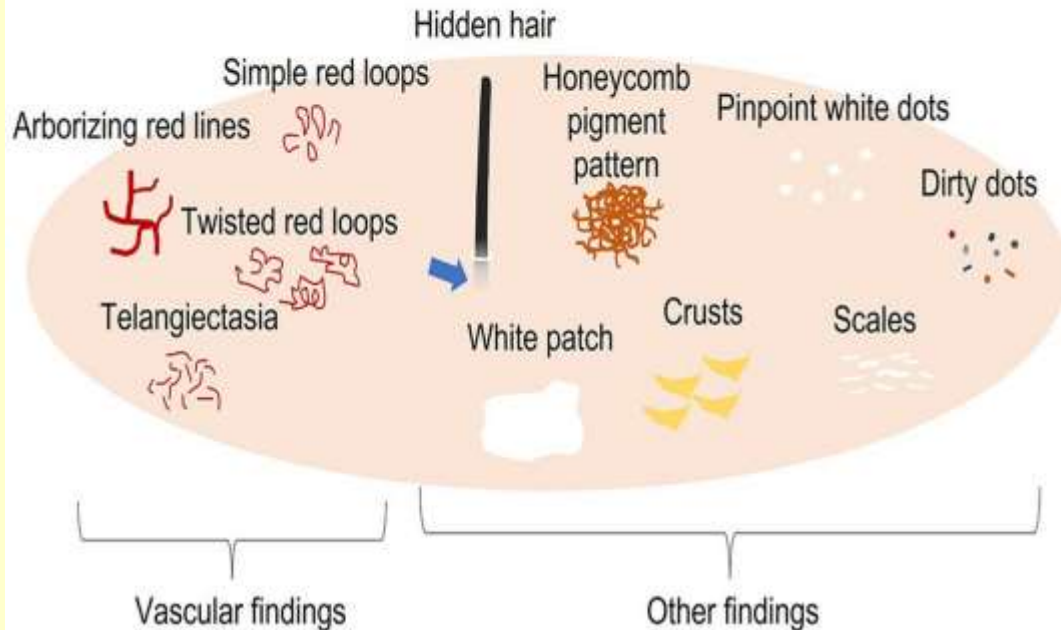
Follicular & perifollicular findings

Follicular and perifollicular findings

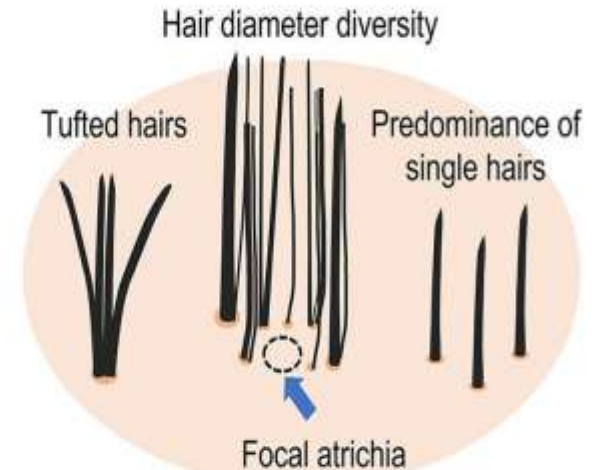

Skin and blood vessel findings

Scalp findings



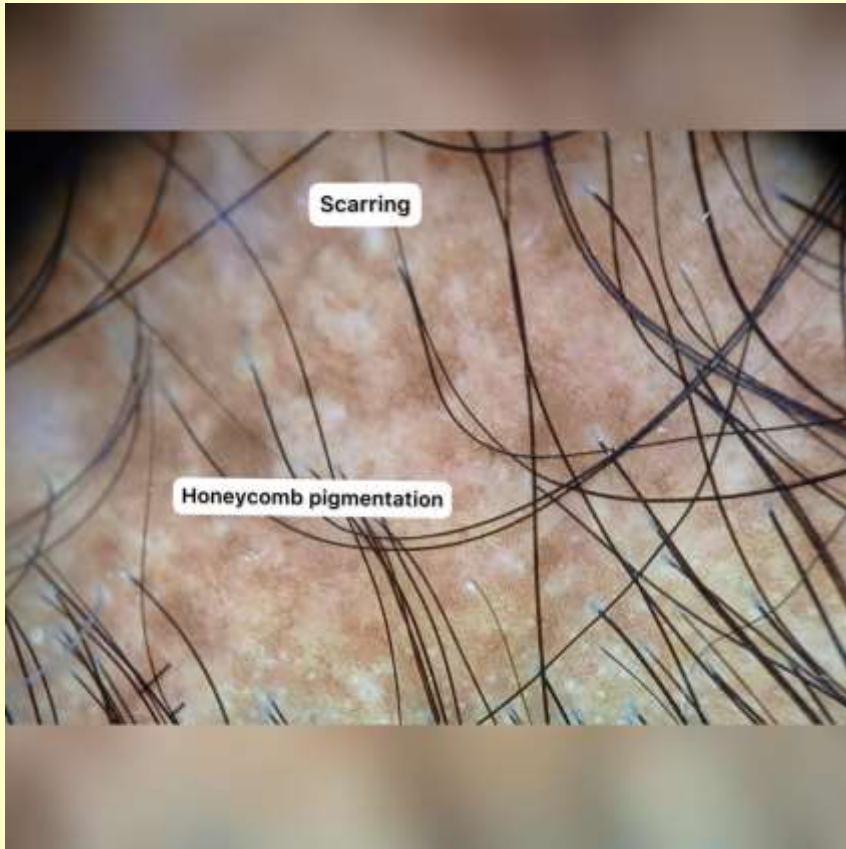
Hair distribution pattern abnormalities



Normal scalp



Cicatricial vs Non Cicatricial



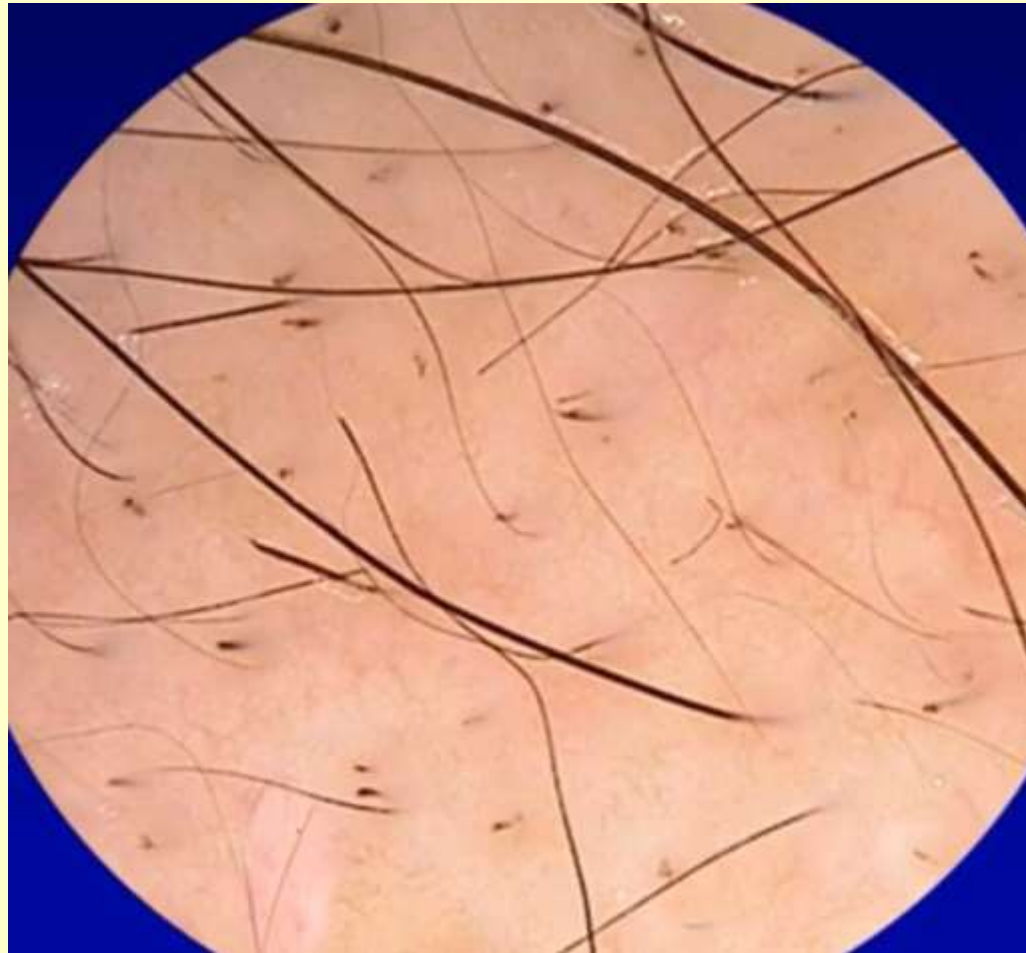
Androgenetic alopecia

- **Hair shaft thickness heterogeneity**
- **>10% vellous hair**
- Perifollicular hyperpigmentation (peripilar sign)
- **↓**No. and miniaturization of follicular hair
- Yellow dots

Alopecia areata

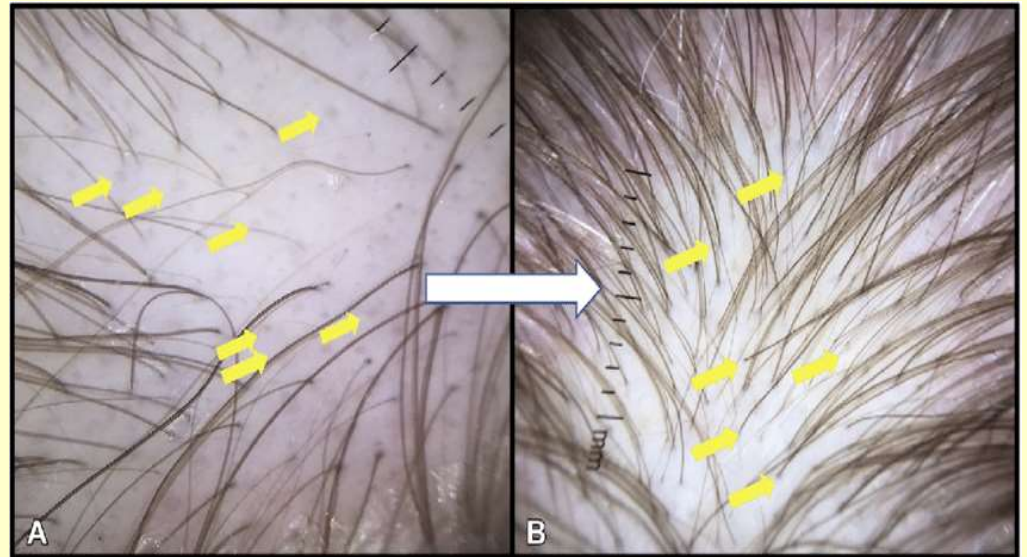
- Exclamation mark hair (short or long)
- Black dots
- Pohl pinkus constriction
- Regrowing hair
- Yellow dots
- Vellus hair
- Upright hair
- Pig tail hair (good prognosis)

Alopecia Areata



Telogen effluvium

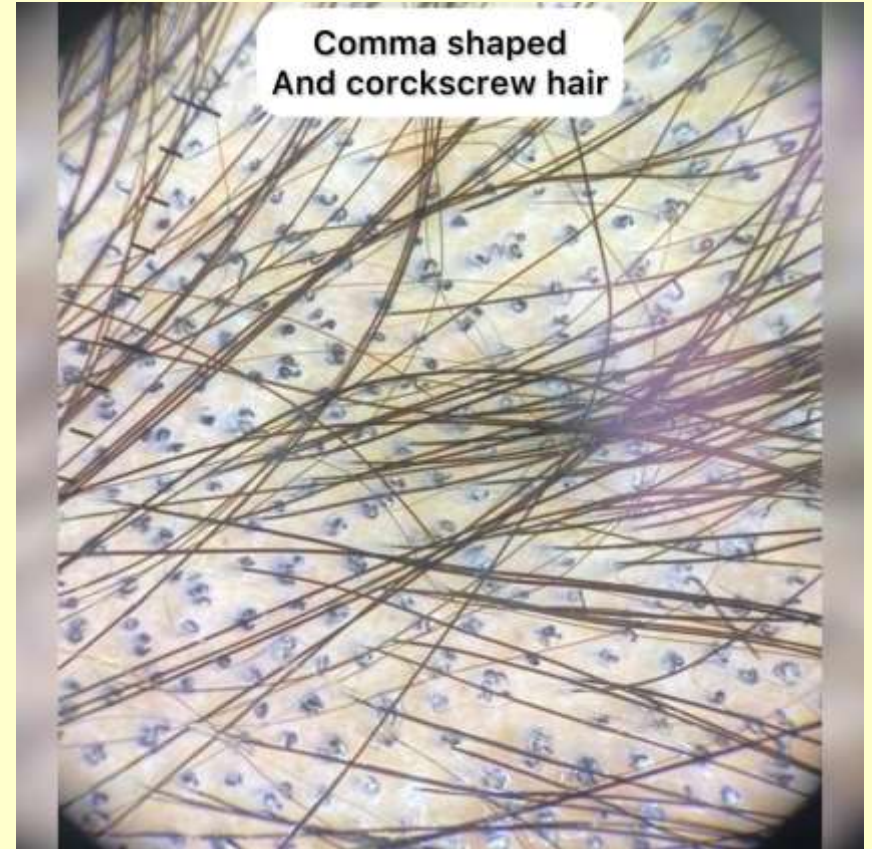
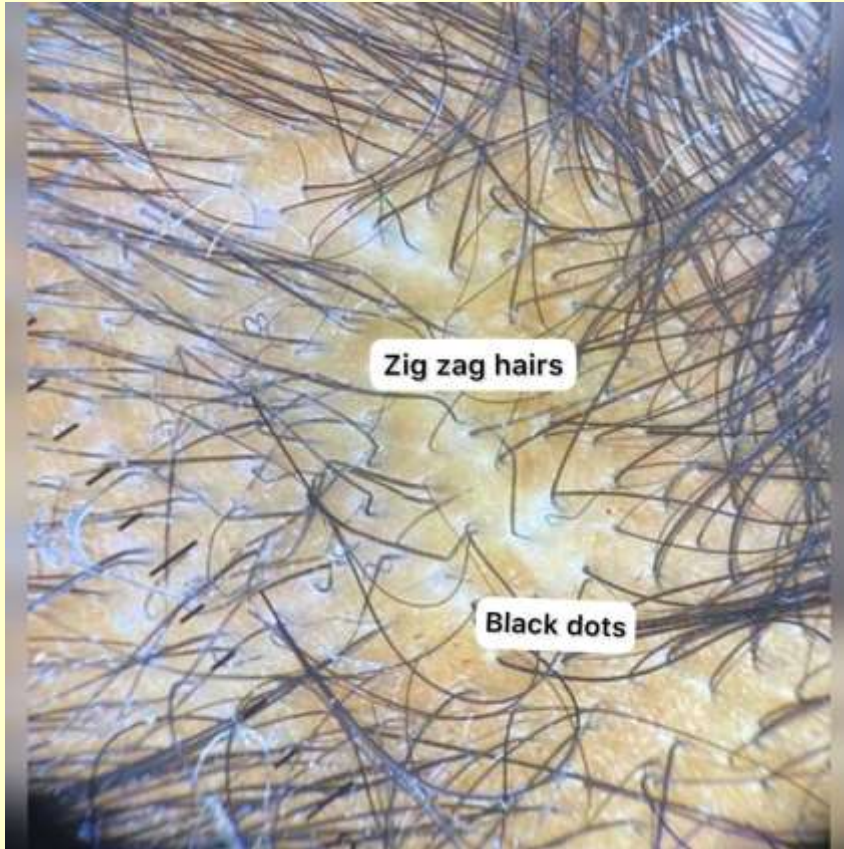
- Diagnosis of exclusion
- Decreased hair density with presence of empty follicles
- Entire scalp



Tinea capitis

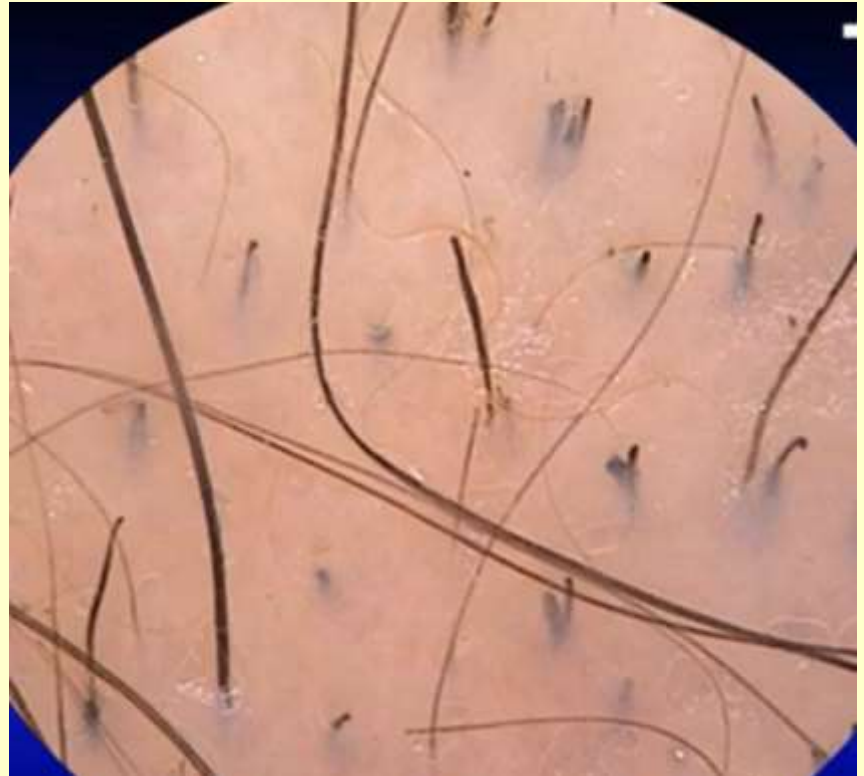- **Comma hair**
- Corkscrew hair
- Zigzag hair
- Morse code hair
- i hair
- Block hairs

Tinea capitis



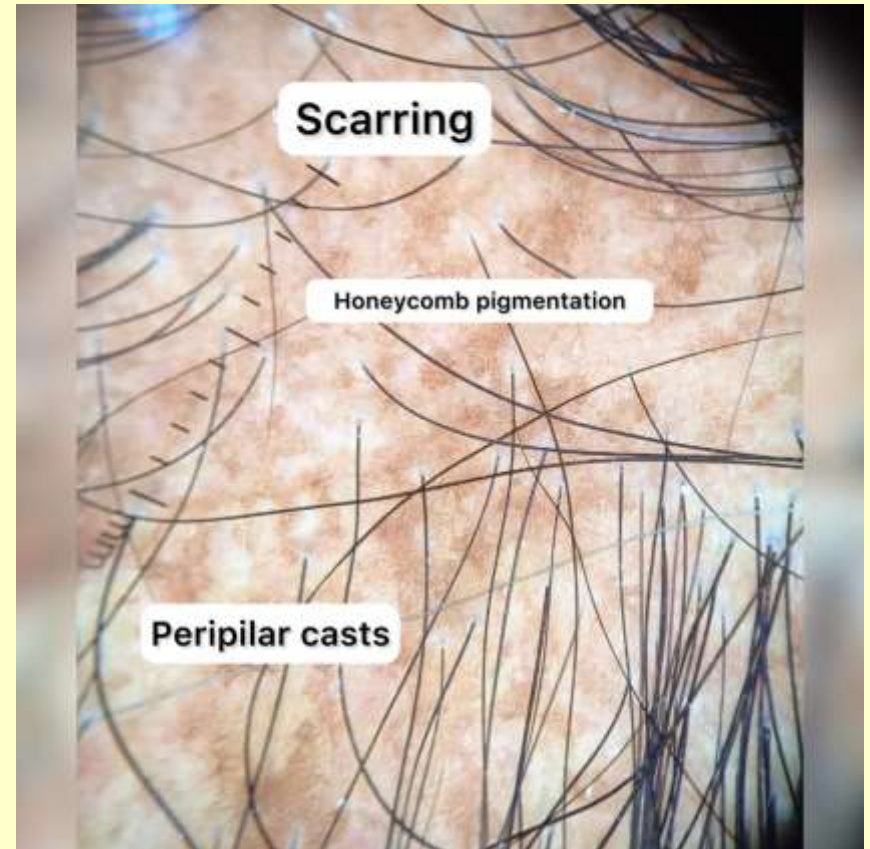
Trichotillomania

- **Hook hairs**
- **Coiled hairs**
- **V sign**
- **Flame hair**
- **Hair powder**
- **Trichoptilosis**
- **Tulip hair**



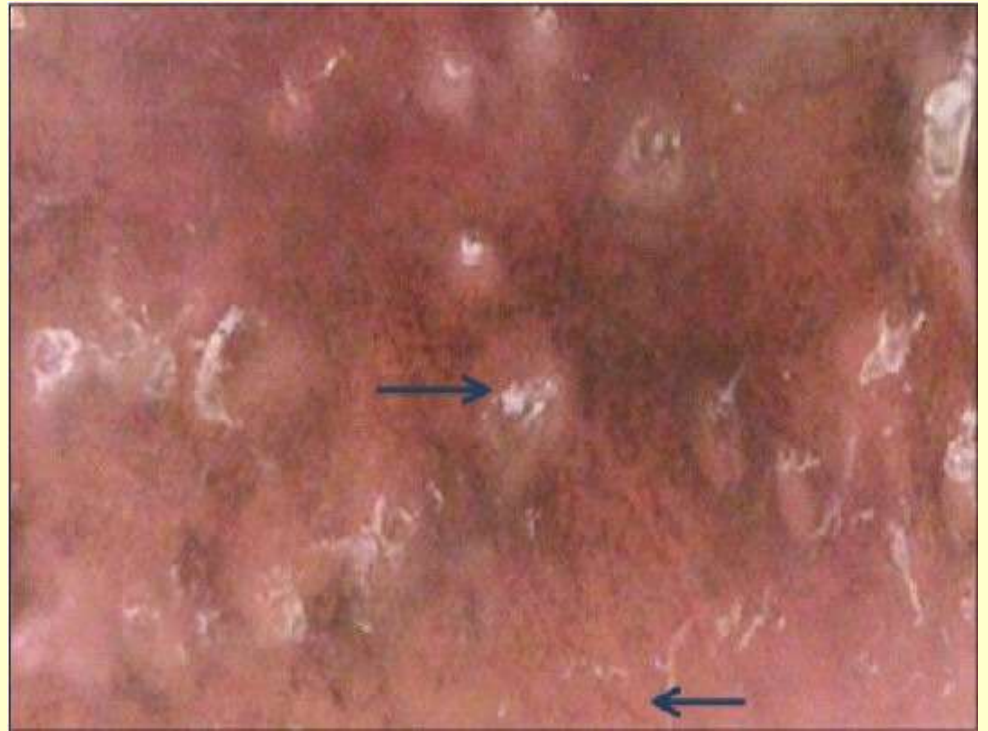Lichen planopilaris

- Peripilar casts
- Blue grey dots ---late white dots
- Interfollicular usually normal



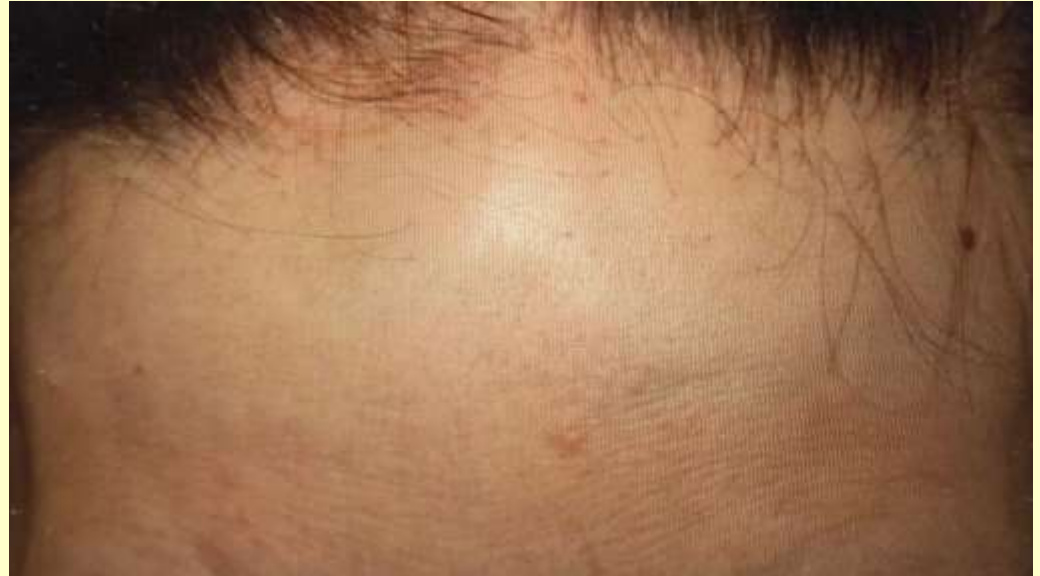DLE

- Atrophy
- Complete follicular paucity
- Arborising telangiectasia
- Hyperkeratotic follicular scales



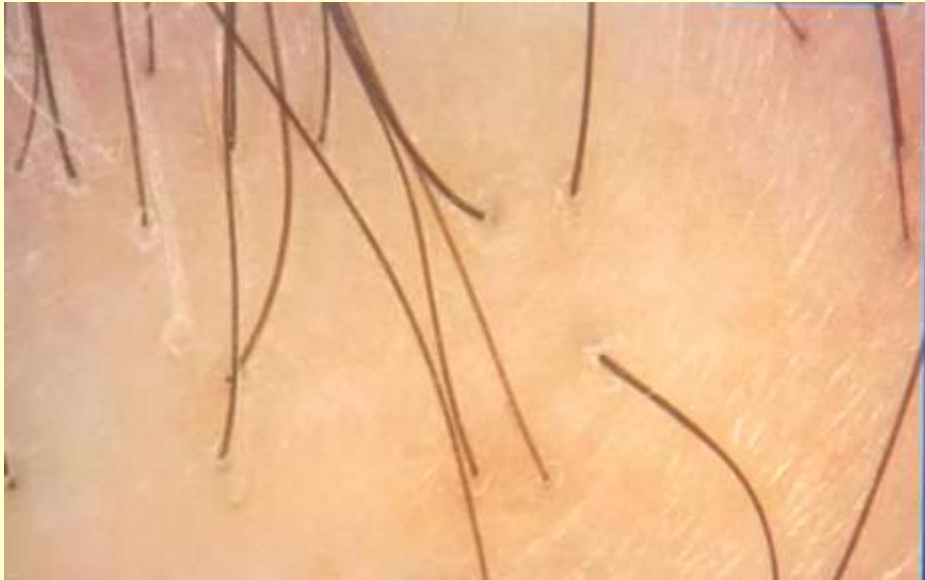
Frontal fibrosing alopecia

- Lonely hair
- Mild perifollicular scaling
- **No vellus hair**

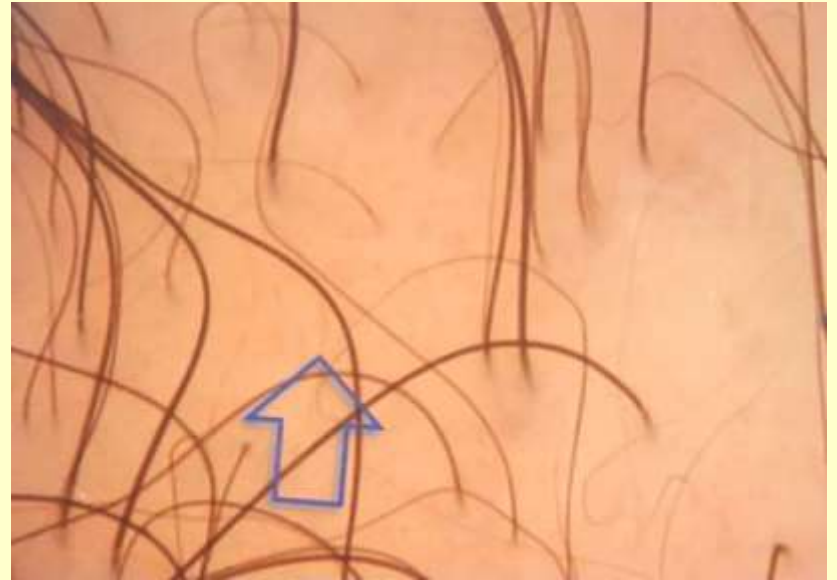

(Clinically regression of frontal hair line, lonely hair & eyebrow loss)

Frontal fibrosing alopecia



Female androgenetic alopecia




Hair shaft disorders-monilethrix

- Mutations in genes encoding keratins-KRT81,KRT83,KRT86 or desmoglein 4
- Hair breaks before max 5 cm
- Variable % of hairs involved




Hair shaft disorders- trichothiodystrophy

- TTDN1, XPB, XPD or TTDA gene
- Dry fragile hairs
- Low intelligence
- Photosensitivity
- Ichthyosis
- “Grains of sand” & transverse fractures
- “Tiger tail”



Summary



Utility of Trichoscopy

- Quick
- Noninvasive
- Obviating unnecessary biopsies
- Choosing Ideal biopsy site
- Response evaluation
- Only problem is overlap of findings in some conditions

Thank You

A scenic mountain landscape. In the foreground, a rocky, gravelly path leads down a slope. The middle ground shows a valley with a stream, green meadows, and scattered trees. In the background, there are large, rugged mountains with patches of snow under a cloudy sky.

- Dr Lidia Rudnicka
- Dr Uday khopkar
- Dr Devyani Pol