

Bacterial Infections

Dr.Snehal Navande-Kodgire

M.D.(Skin & VD)

Asst.prof.

Dept.of Dermatology

MIMER Medical College, Talegaon.

CONTENTS

- Introduction
- Classification
- Primary pyodermas
 - Superficial folliculitis
 - Impetigo
 - Ecthyma
 - Sycosis barbae
 - Furuncle
 - Carbuncle
 - Chronic folliculitis
 - Erysipelas
 - Cellulitis
 - Necrotising fasciitis
 - Paronychia
 - Staphylococcal scalded skin syndrome
 - Toxic shock syndrome
 - Corynebacterial infections
- Secondary pyodermas
- Management principles

Introduction

- Pyoderma: Bacterial infections of skin.

- Caused by mainly 2 Gram positive organisms:
 - *Staphylococcus aureus* : Intact skin
 - Group A beta-hemolytic *Streptococci* : Traumatic skin

- Other bacteria:
 - *Corynebacteria*
 - *Kytococcus* (Erstwhile *Micrococcus*)
 - *Pseudomonas*

Classification : Pyoderma

■ Primary

- Primary pyodermas occur without any predisposing conditions.
 - Superficial :
 - Follicular : Superficial folliculitis
Follicular impetigo
 - Non-follicular : Impetigo
 - Deep :
 - Follicular : Sycosis barbae, Furuncle, Carbuncle
 - Non-follicular : Ecthyma, Cellulitis, Erysipelas, Paronychia, Necrotising fasciitis

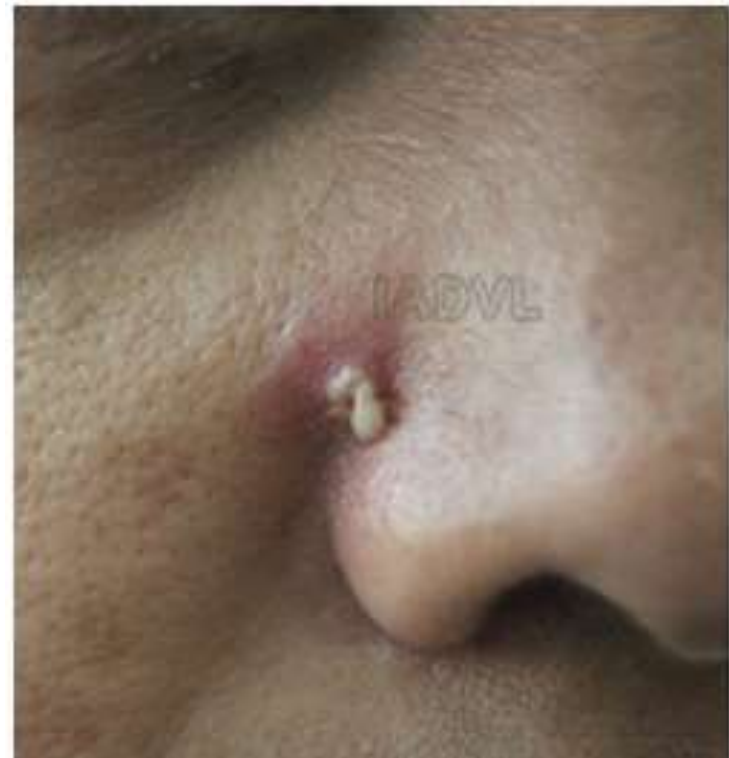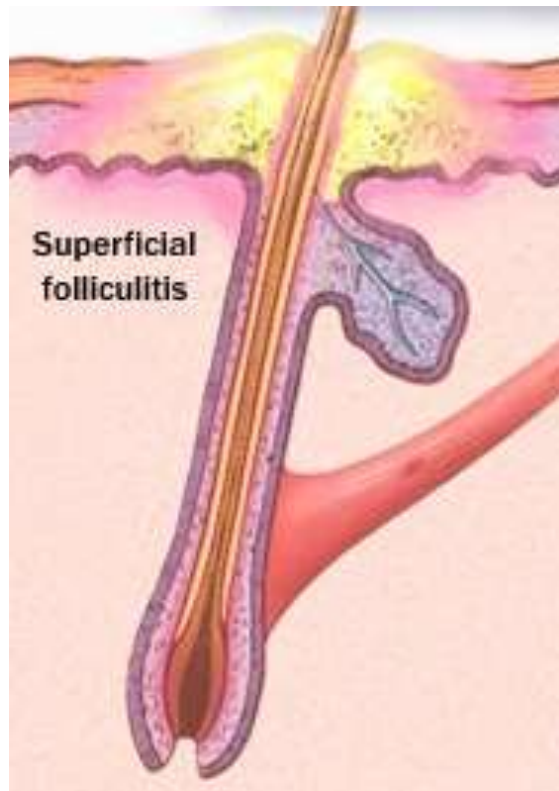
■ Secondary

- may occur secondary to pre-existing dermatoses like eczemas, vasculitic ulcers etc.
 - Infected eczemas, Infected ulcers, etc

Superficial Folliculitis

- Superficial infection of the hair follicle
- *Staphylococcus aureus*
- Scalp and face
- Follicular pustules with a rim of erythema

Superficial Folliculitis

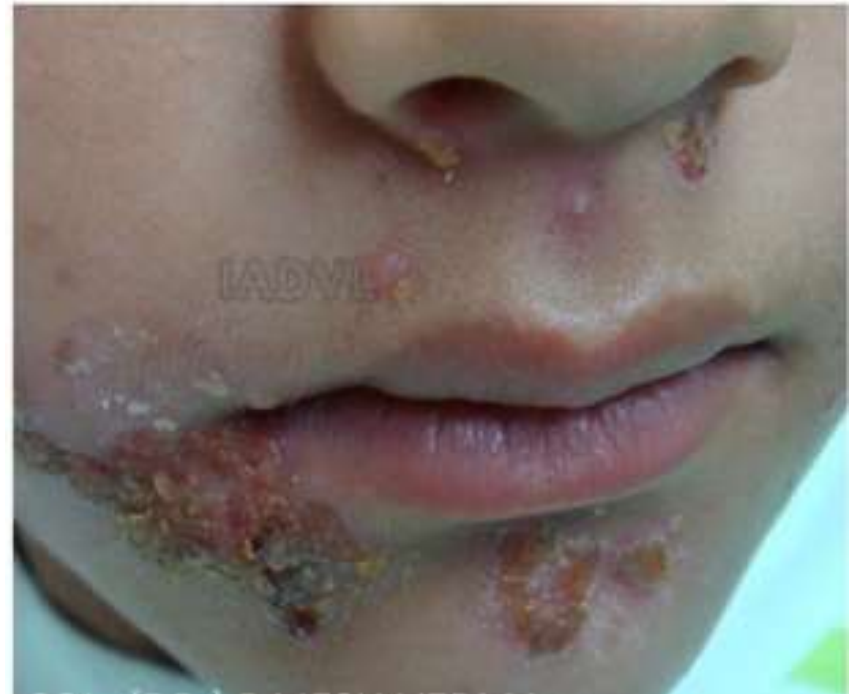

Impetigo

- Pre-school children
- Face, arms, legs
- Predisposing factors: close contact, atopic dermatitis, warmth, poor hygiene, minor trauma etc.
- *Staphylococcus aureus*, Group A beta hemolytic *Streptococci*
- **Clinical types :**
 - Impetigo Contagiosa
 - Bullous Impetigo

Impetigo Contagiosa

- Predilection for peri-oral and peri-nasal area.
- Honey-coloured crusted plaques.
- Heal without scarring



Peri-oral & peri-nasal area showing
Impetigo Contagiosa

Bullous Impetigo

- Bullous impetigo is caused by an Epidermolytic Toxin.
- Produced at the site of infection by *Staphylococcus aureus*.
- Causing intra-epidermal cleavage, clinically manifesting as - Bullae.

Bullous Impetigo

Vesicles / Bullae with

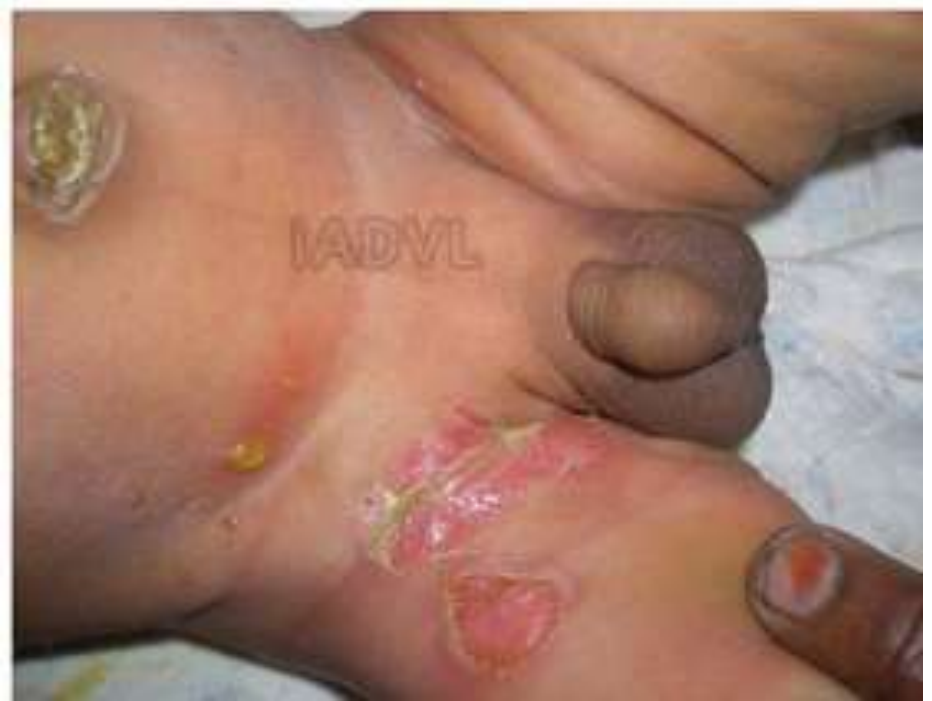Clear / Turbid fluid



Brownish crusts



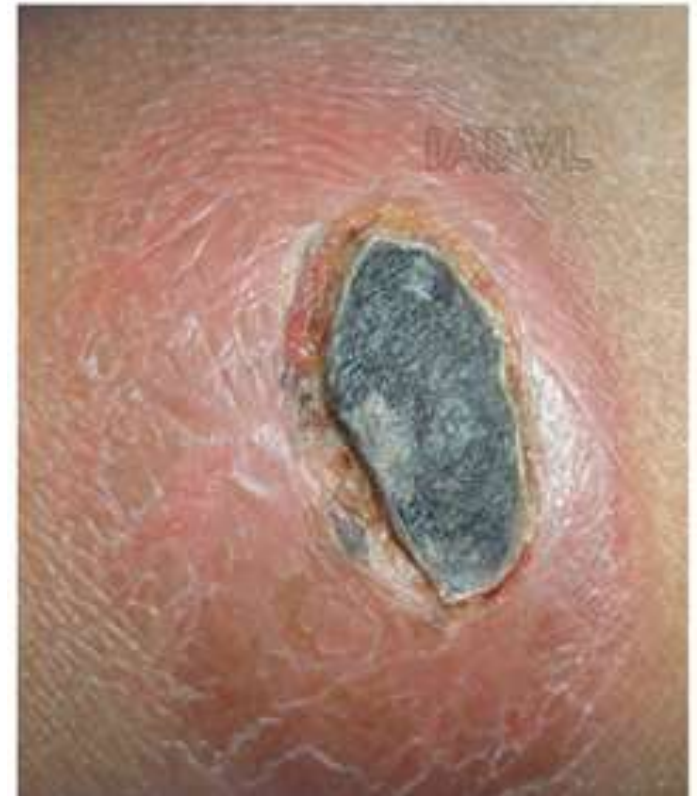Moist erosions.



Lower abdomen and groin of an infant with Bullous Impetigo

Ecthyma

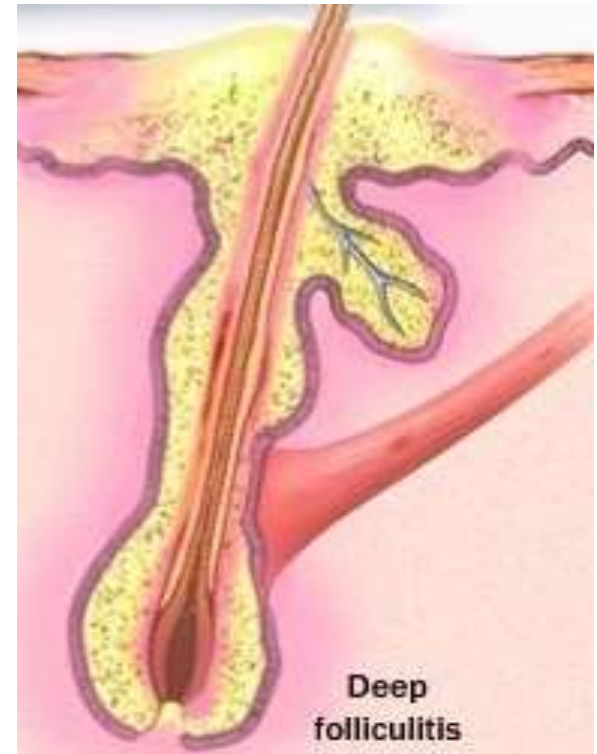- Diabetes, Immune-compromised
- Legs & buttocks
- Thick, chocolate coloured, adherent crust, with a rim of erythema.
- When removed, a punched-out ulcer results.
- Heals with scarring.



Thigh of a patient with Ecthyma

Deep Folliculitis : Types

- Sycosis barbae
- Furuncle(Boil)
- Carbuncle



Sycosis barbae

-*Staphylococcus aureus*

- Erythematous follicular
discrete papules or pustules

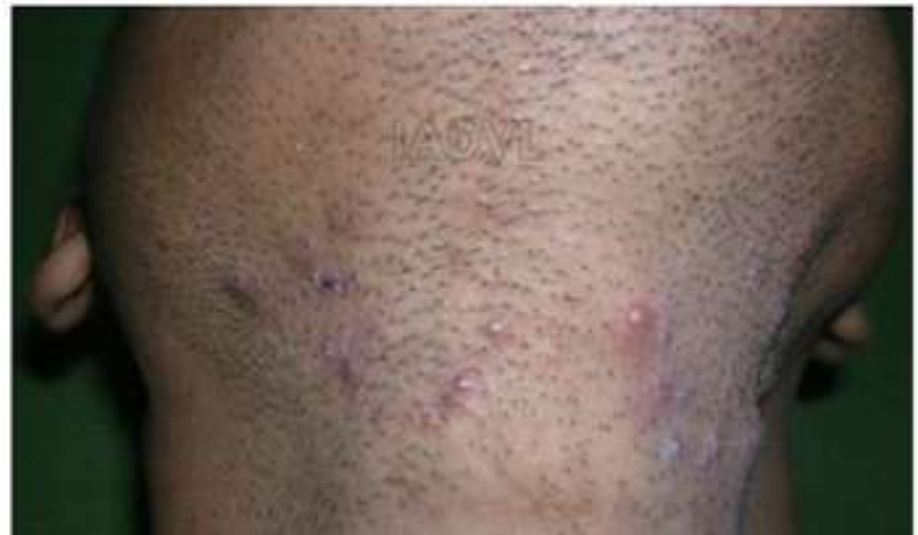

Coalesce



Raised plaque,
studded with pustules.

-“Fig like” appearance

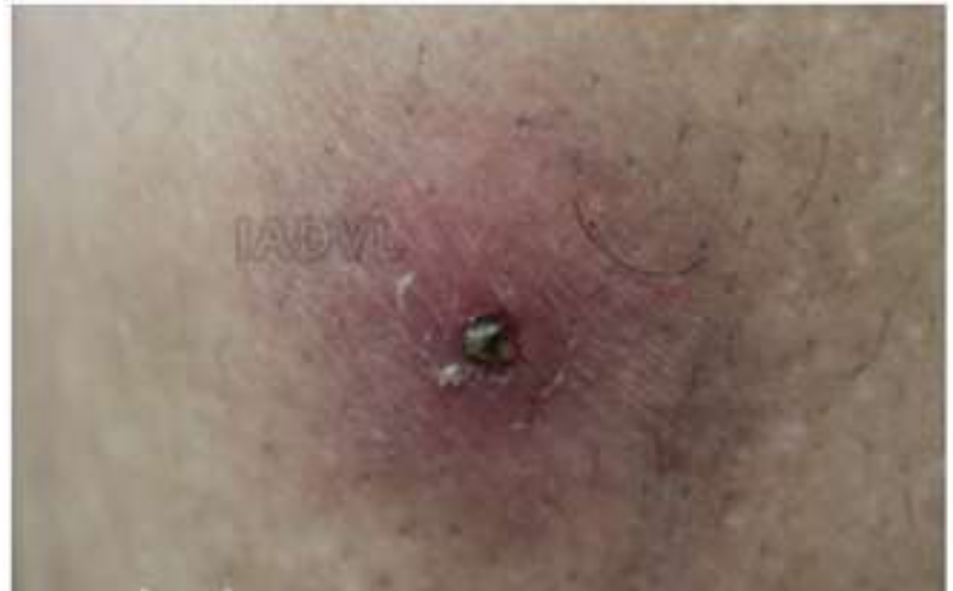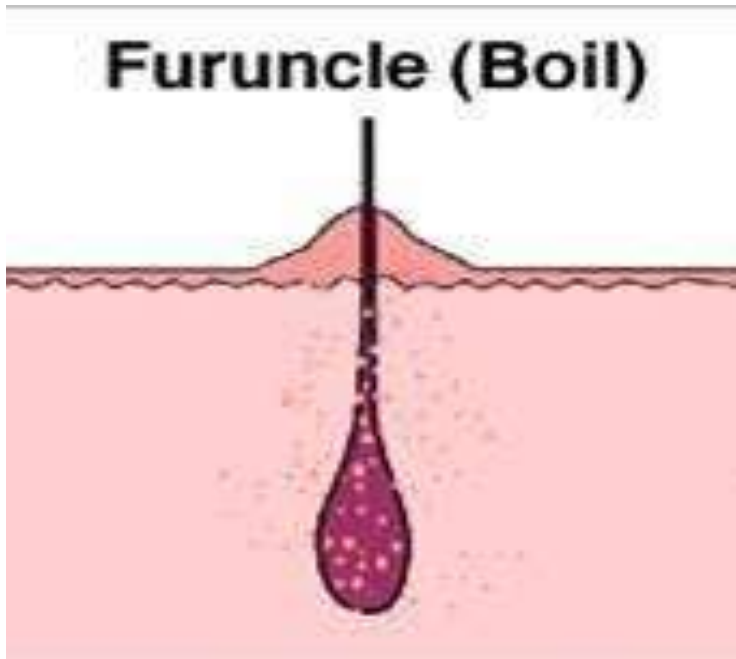


Beard region in a patient with
Sycosis barbae

Furuncle

- Acute, deep infection of a hair follicle.
- Hair bearing areas.
- *Staph aureus*.
- Tender, inflammatory nodule.
- Pus discharge.
- Heals with scarring.

Furuncle

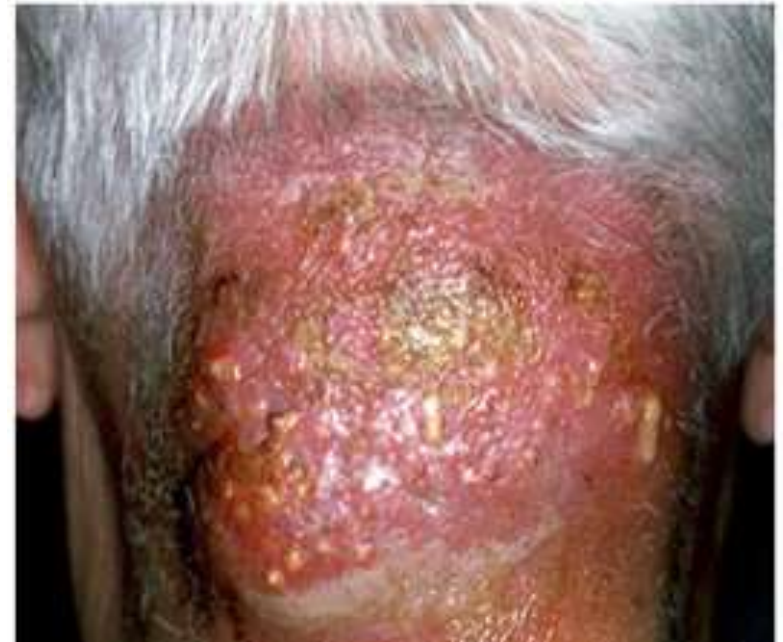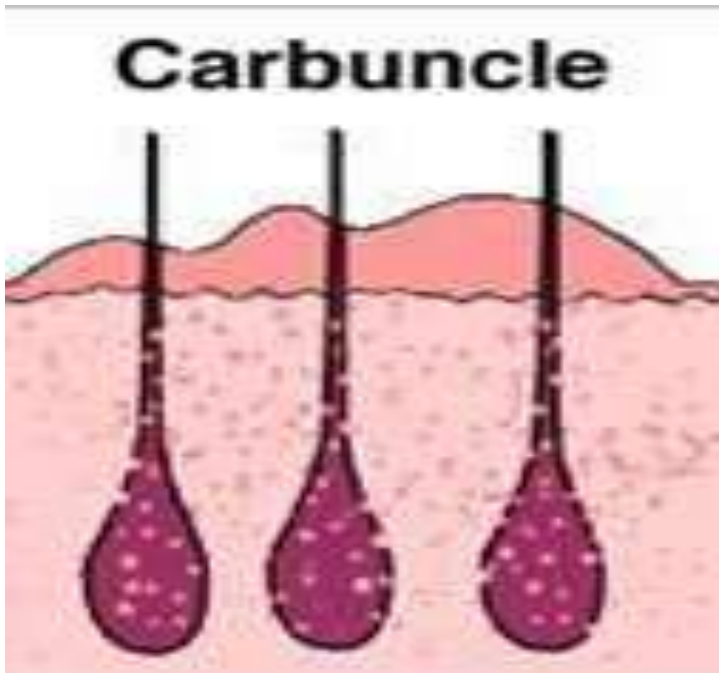


Thigh of a patient, showing a Furuncle

Carbuncle

- Deep infection of a group of contiguous hair follicles.
- Diabetes, immune-compromised.
- Nape of neck, shoulders, hips and thighs.
- Pus discharge from multiple points- "Sieve like appearance".

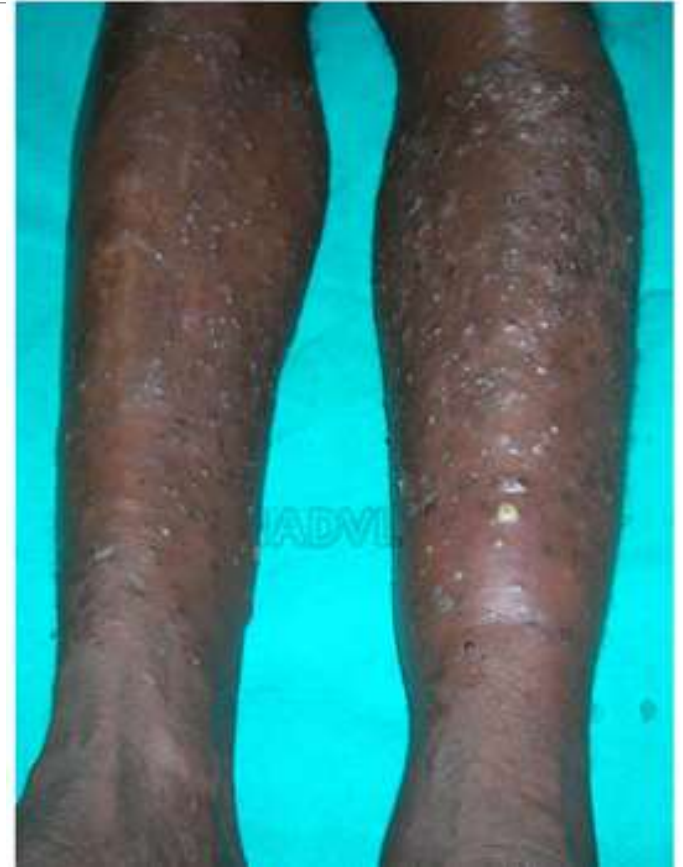Carbuncle



Nape of neck with Carbuncle

Chronic Folliculitis

- DCPA (Dermatitis Cruris Pustulosa et Atrophicans)
- Recalcitrant, lasting for several years.
- Young Indian males
- Involves anterior aspect of lower legs bilaterally; may extend up to the thigh.
- Usually clears after development of atrophy



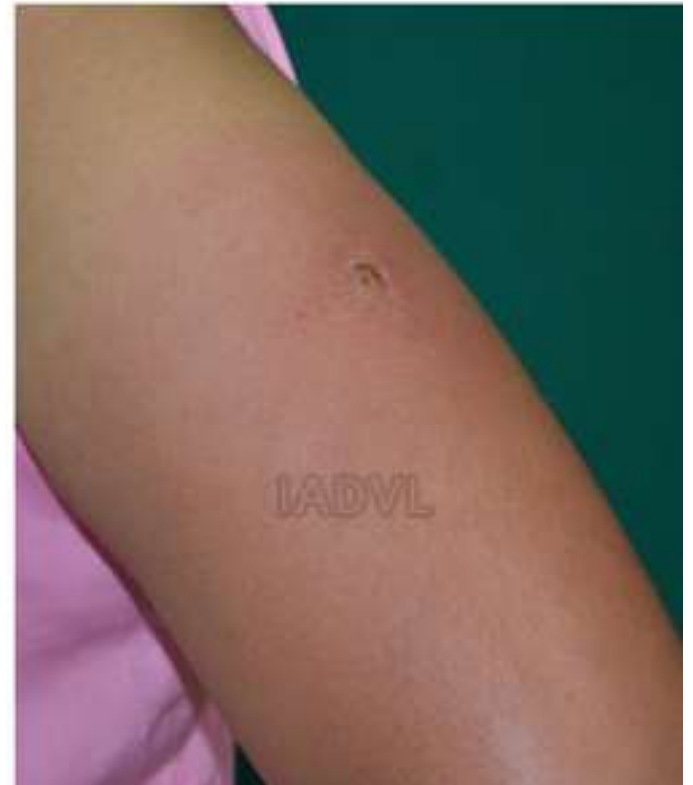Legs of a patient with Chronic Folliculitis

Erysipelas and Cellulitis

- Soft tissue infections of skin.
- Group A beta-hemolytic *Streptococci*
- *Staphylococcus aureus*
- Characterised by
 - Local : Erythema, edema, tenderness, pain.
 - Regional: Lymphangitis, Lymphadenitis
 - Systemic: Fever, Leukocytosis

Erysipelas

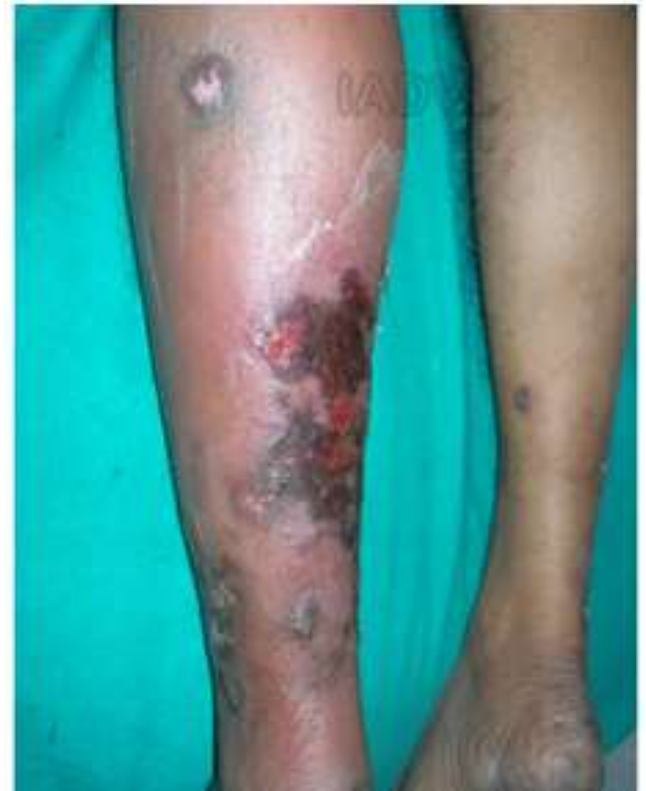- Group A beta-hemolytic *Streptococci*
- Superficial dermis & lymphatics
- Raised plaque
- Well demarcated edge
- Warm and tender



Arm of a patient with Erysipelas

Cellulitis

- *Staphylococcus aureus* or Group A beta-hemolytic *Streptococci*
- Deeper dermis & subcutaneous tissue
- Diffuse edge- not well demarcated
- Warm and tender
- The surface may show focus of pus and necrosis, which may ulcerate



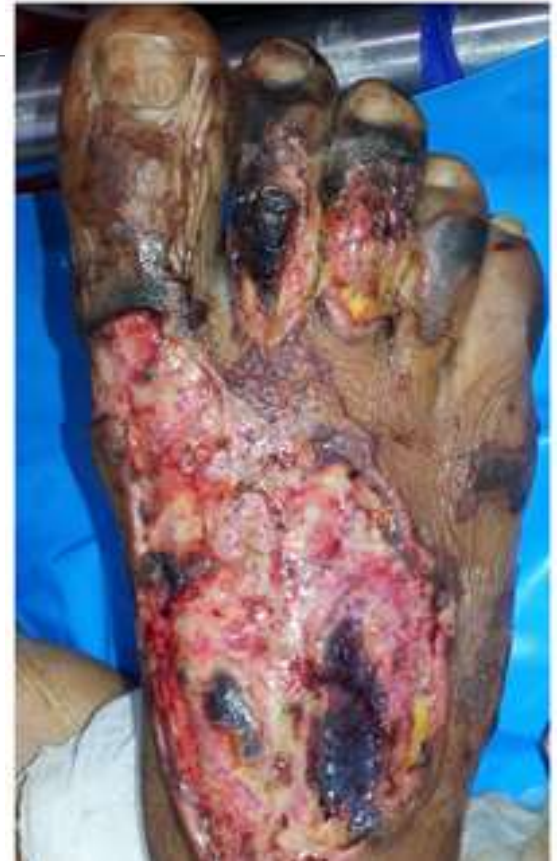Left leg with Cellulitis

Necrotising Fasciitis

- Progressive destruction of
 - Muscle fascia
 - Overlying subcutaneous fat.
- Muscle tissue is frequently spared: generous blood supply.
- In initial stages- the overlying tissue may appear unaffected.
- It is this feature that makes necrotizing fasciitis difficult to diagnose without surgical intervention.

Necrotising Fasciitis

- The affected area may become erythematous, edematous, warm, shiny, and exquisitely tender.
- If diagnosis is delayed- skin breakdown and frank cutaneous gangrene results.
- Compartment syndrome: surgical emergency.
- Fasciotomy



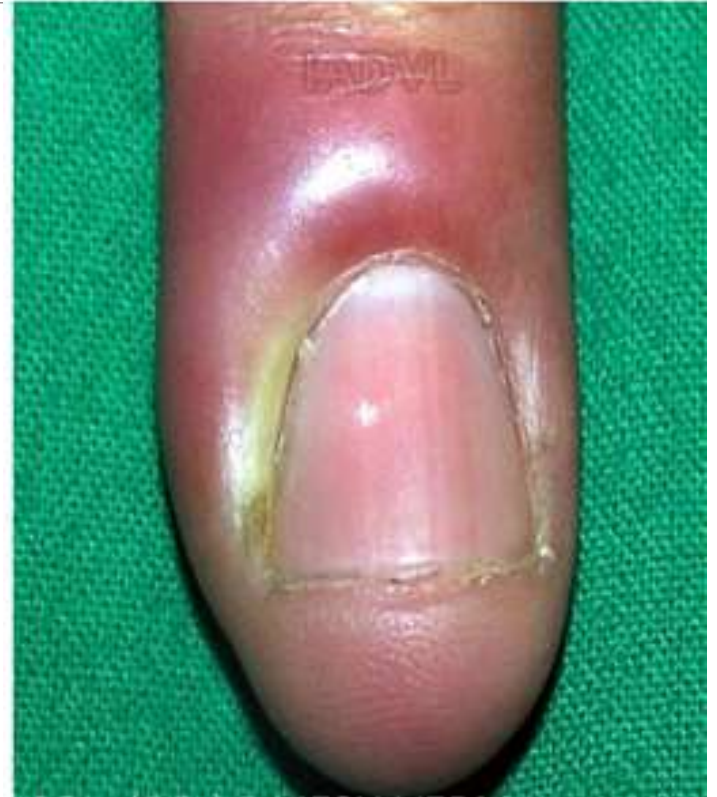Dorsum of right foot and toes with necrotising fasciitis.

Paronychia

- Paronychia is the infection of the lateral and/or of the proximal nail folds.
- **Predisposing factors** - Cuticular damage
 - Overzealous manicuring, especially with unsterile instruments.
 - Nail biting, thumb-sucking
 - Diabetes mellitus
 - Ingrown toe nail
 - Occupations in which the hands are frequently immersed in water. (home-makers, chefs etc)
- **Classified as:**
 - Acute
 - Chronic

Acute Paronychia

- Characterized by acute onset of pain and erythema of the posterior and/or lateral nail folds.
- With subsequent development of a superficial abscess.
- *Staphylococcus aureus* and Group A beta-hemolytic *Streptococci*



Nail with Acute Paronychia

Acute Paronychia

■ Treatment:

- Topical :
 - Warm compresses or soaks
 - Topical antibiotics
 - Systemic antibiotics & NSAIDs
- } without abscess
- Systemic :
 - Antibiotics
 - NSAIDs
 - Surgical :
 - Incision and drainage.
- } with abscess

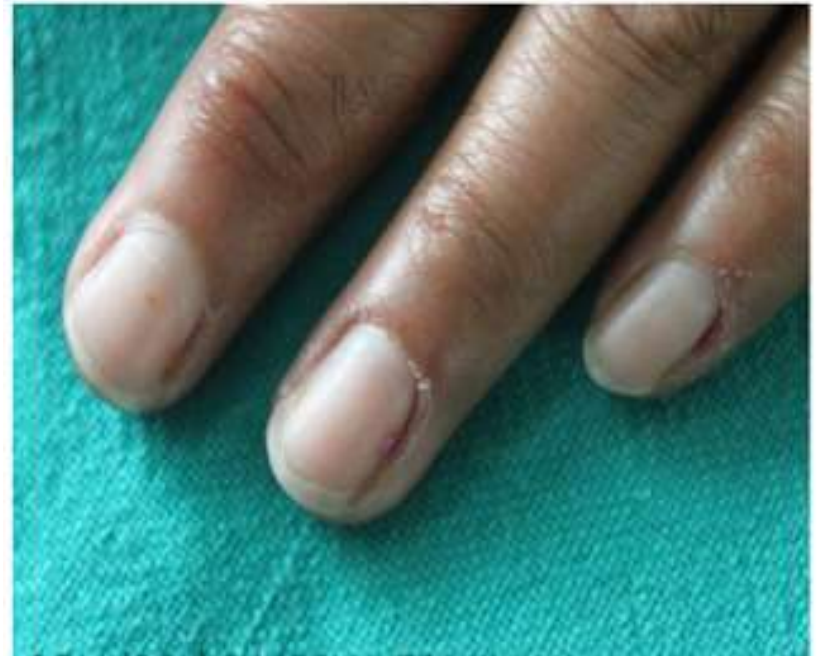Chronic Paronychia

■ Etiology :

- Damage to cuticle of nail
- Chronic Eczema
- Chronic *Candida* infection

■ Treatment :

- Difficult to treat
- Keeping hands as dry as possible
- Avoid irritants and allergens
- Topical anti-fungals and corticosteroids



Middle, ring and little fingers
with Chronic Paronychia

Staphylococcal Scalded Skin Syndrome

- A disease affecting the neonates, infants and young children.
- Febrile and irritable
- Diffuse blanching erythema and flaccid blisters, especially in flexural areas, buttocks, hands and feet.
- Gentle pressure applied to the skin results in separation of the upper epidermis from the underlying dermis. (Nikolsky's sign).

Staphylococcal Scalded Skin Syndrome

Foci of infection of
Staphylococcus aureus.



Epidermolytic toxin



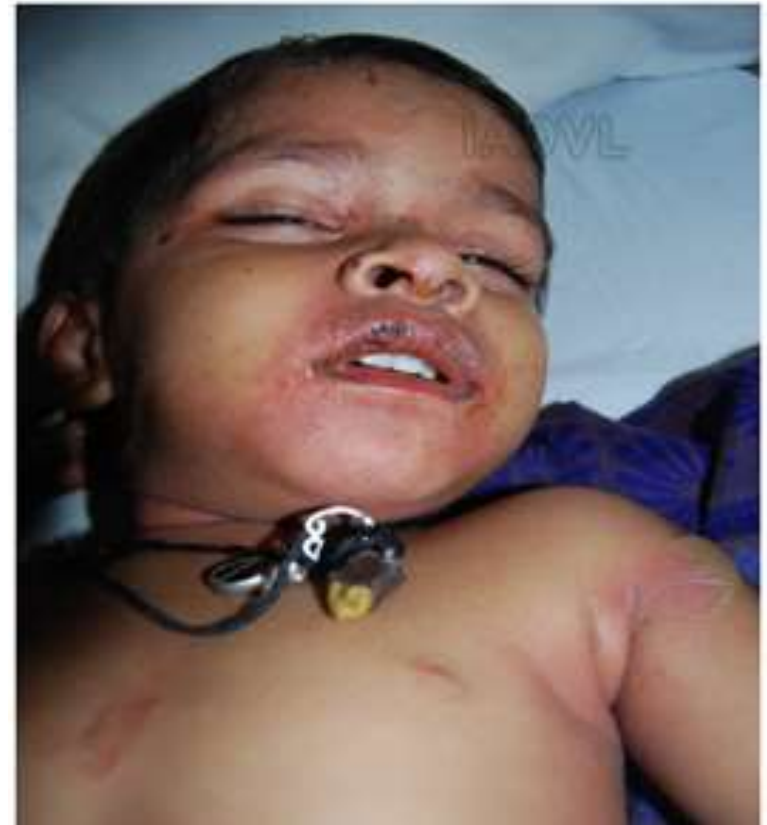Acts on intra-epidermal desmosome
complex



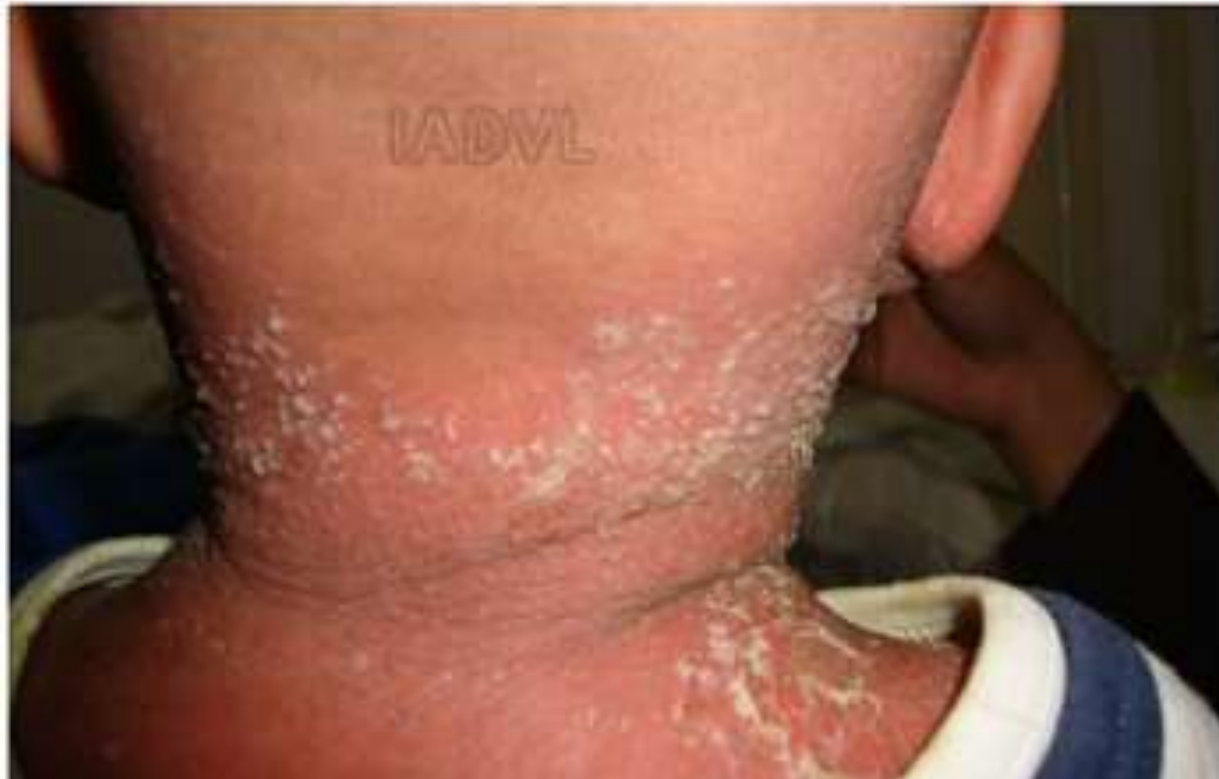Fragile, tense bullae
and vesicles



Erosions



Staphylococcal Scalded
Skin Syndrome



Neck of a child with Staphylococcal Scalded Skin Syndrome : showing widespread peeling of skin, on a background of diffuse erythema.

Toxic Shock Syndrome

- Acute febrile multisystem disease.
- *Staphylococcus aureus* toxin- mediated disease.
- TSST-1: Toxic Shock Syndrome Toxin-1
- Predisposed individuals: Post surgical and those with catheters and canulae.
- Diffuse erythema of body with systemic symptoms.
 - Systemic antibiotics
 - Intensive supportive treatment

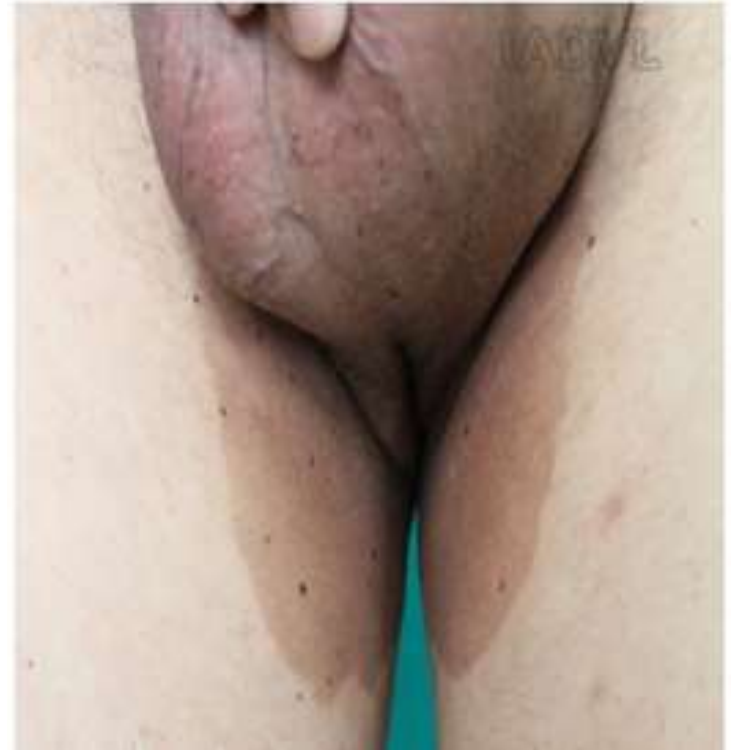Toxic Shock Syndrome

■ Cardinal signs and symptoms :

- Fever with chills
- Myalgia
- Dizziness, headache, syncope and hypotension
- Diffuse erythema
- Reduced urine output
- Edema of extremities
- Severe diarrhoea, nausea, vomiting and abdominal pain
- Confusion, dizziness, irritability, agitation and hallucination.

Erythrasma

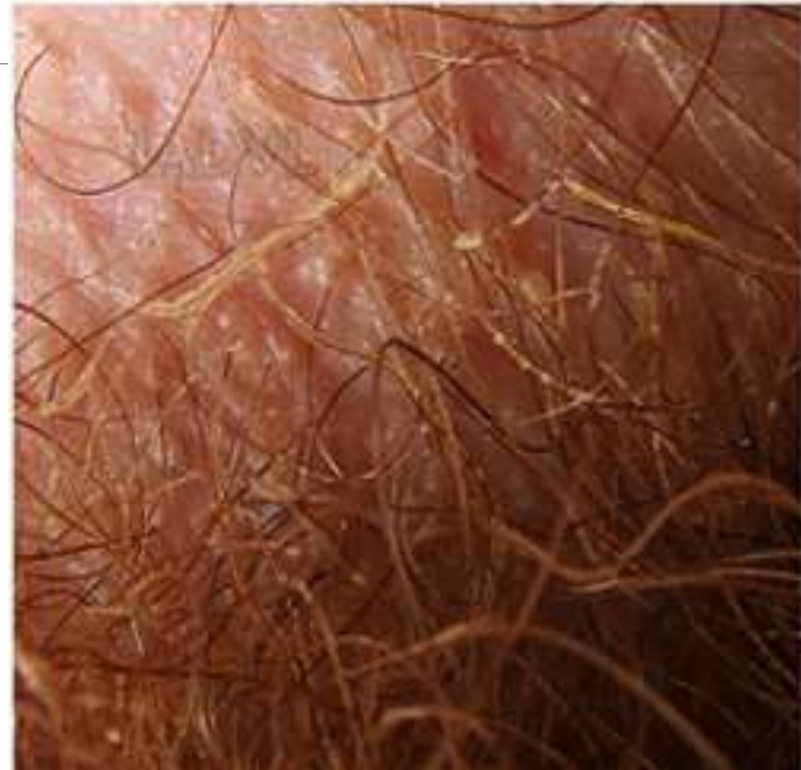
- *Corynebacterium minutissimum*
- Asymptomatic red-brown macules, plaques at body folds
- Wood's lamp: Coral Red fluorescence.
- Oral : Erythromycin
- Topical : Fusidic acid



Groin fold showing a hyperpigmented macule- Erythrasma

Trichomycosis Axillaris

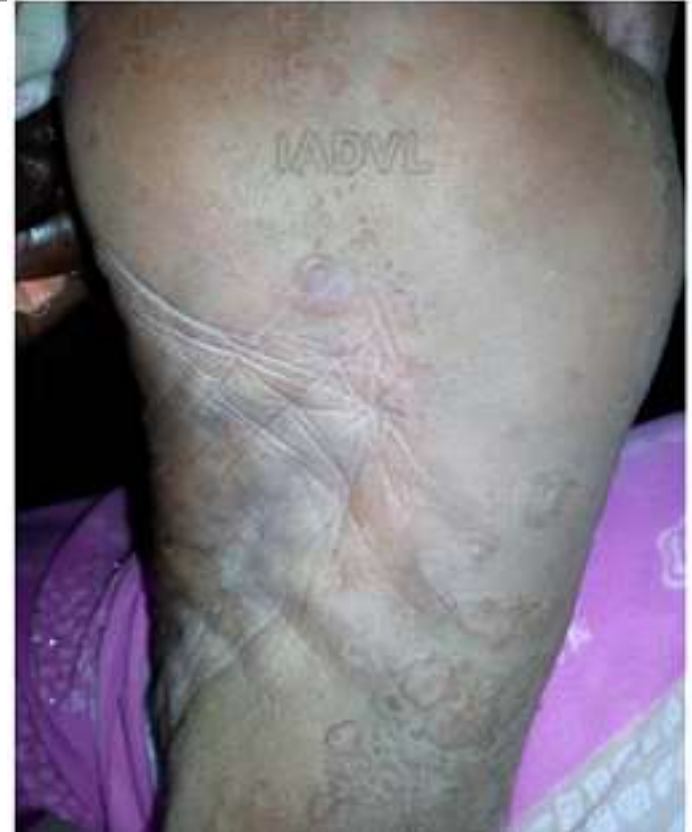- Corynebacteria
- Axillae and groin
- Adherent yellow, brown-black deposits on hair shaft.
- Topical : Clindamycin
- Shaving/clipping.
- Systemic : Erythromycin



An up close clinical photograph of axilla of a patient with Trichomycosis axillaris

Pitted Keratolysis

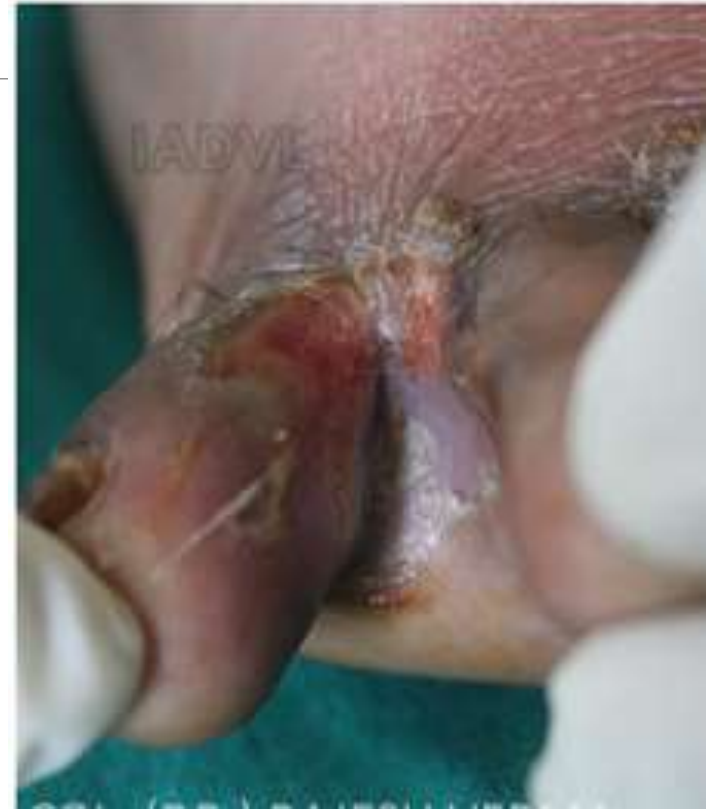- *Kytococcus sedentarius* (*Micrococcus sedentarius*).
- Hyperhidrosis of feet; occlusive footwear
- Foot odour, itching
- Discrete / confluent pits
- Oral: Erythromycin
- Topical: Fusidic acid, Benzoyl Peroxide



Sole with Pitted Keratolysis

Secondary Pyodermas

- Pyodermas developing in a pre-existing dermatosis.
- e.g. infected eczema, infected vasculitic ulcer etc.



Pyoderma secondary to Candidial Intertrigo of 4th web space of the foot.

Management Principles

■ **Identify and assess the predisposing factors :**

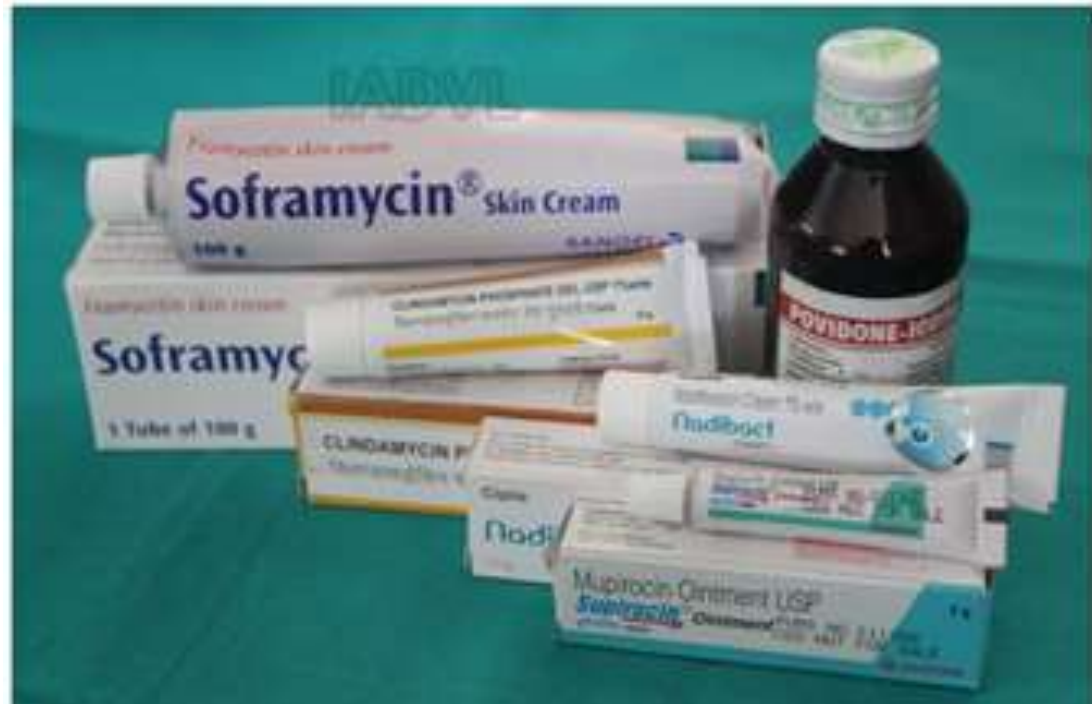- Poor hygiene
- Malnutrition
- Recurrent trauma
- Diabetes mellitus
- Pre existing skin diseases
- Congenital and acquired Immunodeficiency

■ **Investigations :**

- Work up for any predisposing factors.
- Smear, Culture and Antibiotic Sensitivity test (SCABS).

Management Principles : Topical Therapy

- Soaks / compresses : Condy's solution (KMNO₄)
- Topical antibiotics:
 - Mupirocin
 - Framycetin
 - Sisomicin
 - Nadifloxacin
 - Neomycin
 - Gentamicin
 - Polymyxin B
 - Bacitracin
 - Fusidic acid



Topical agents used in the treatment of Pyodermas

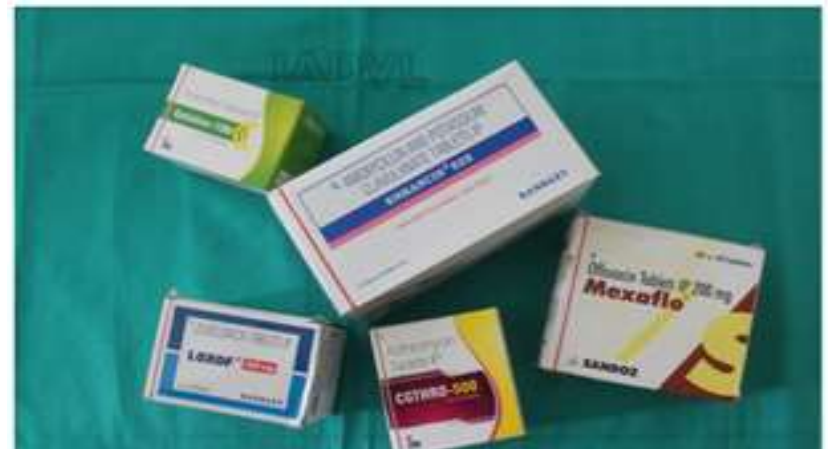Management Principles : Systemic Therapy

■ **Indications of systemic therapy :**

- Fever, tachycardia
- Regional lymphadenopathy
- Danger area of face
- Pyodermas not responding to topical therapy
- Rapidly progressing pyodermas

■ **Available systemic agents**

- Semi-synthetic Penicillins
- Cephalosporins
- Macrolides
- Tetracyclines
- Quinolones



Some of the available systemic agents

MCQ'S

Q.1) Toxic Shock syndrome is caused by

- A. TSST-1
- B. TSST-2
- C. TSST-3
- D. TSST-4

Q.2) Drug of choice for Erythrasma is :

- A. Dicloxacillin
- B. Amoxicillin + Clavulanic acid
- C. Doxycycline
- D. Erythromycin

MCQ'S

Q.3) Bullous impetigo is caused by

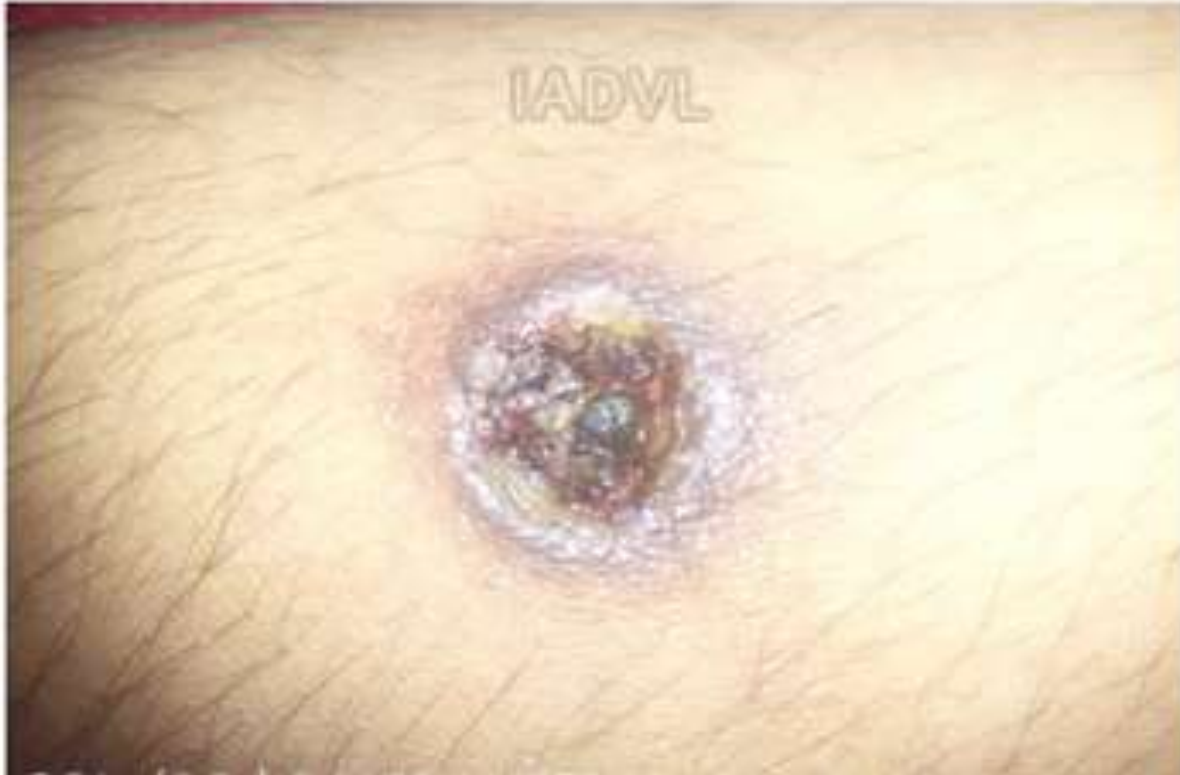- A. *Staphylococcus aureus*
- B. Group A beta- hemolytic *Streptococci*
- C. *Corynebacteria minutissimum*
- D. *Hemophilus influenza*

Q.4) The organism causing Pitted Keratolysis- *Kytococcus* was previously known as

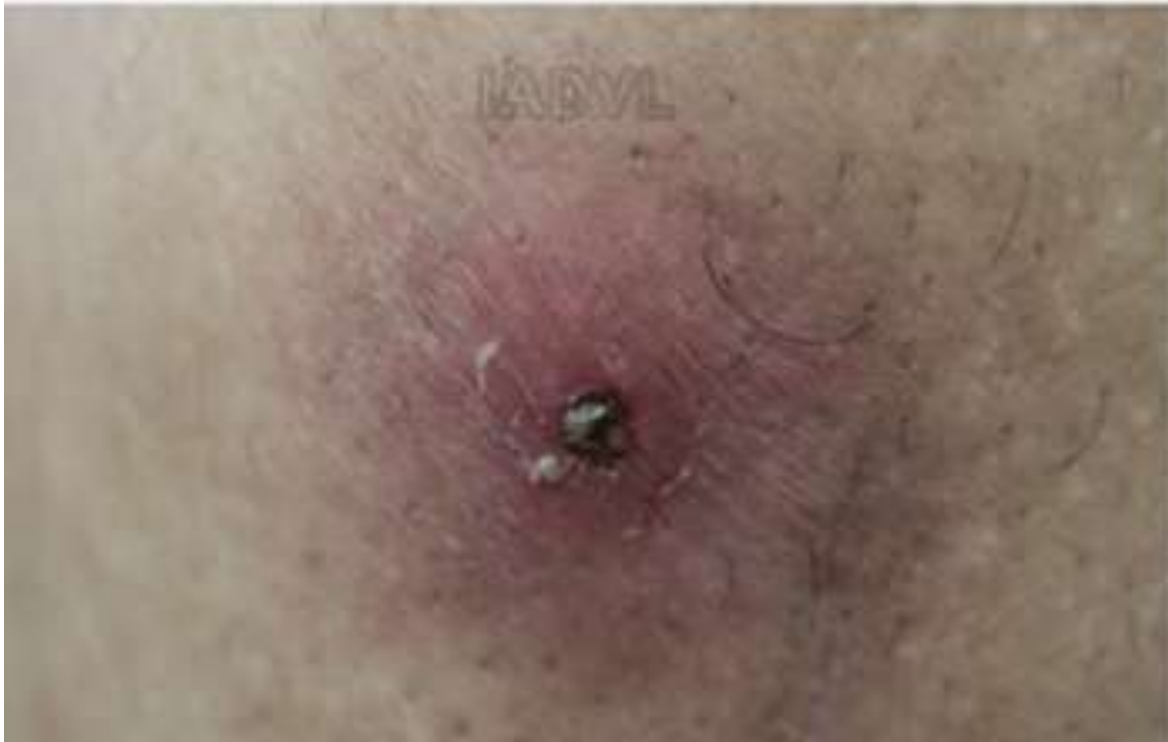- A. *Streptococcus*
- B. *Peptostreptococcus*
- C. *Corynebacteria*
- D. *Micrococcus*

MCQ'S

- Q.5)** A 3 month old infant, presented to the Dermatology OPD with diffuse erythema of the body with fever and irritability of 02 days and flaccid blisters on neck and axillae of 01 day duration. On examination, Nikolsky's sign was found to be positive. What is the likely diagnosis?
- A. Toxic Shock Syndrome
 - B. Staphylococcal Scalded Skin Syndrome
 - C. Bullous impetigo
 - D. Impetigo contagiosa



Q. What is the Diagnosis?



Q. What is the Diagnosis?



Q. What is the Diagnosis?

Thank You!