



# THE OSTEON POST

The Quarterly Newsletter of the Department of Orthopaedics,  
MAEER MIT Pune's MIMER Medical College, Talegaon (D)

5<sup>th</sup> Edition,  
1<sup>st</sup> Feb 2024  
Issue #5

**Issue #5** Editor: Dr Darpan Maheshgauri  
(Professor)

Secretary: Dr. Shubham Chaudhari (Junior Resident)

Contributors: Entire department


*It gives us immense pleasure to release the second volume of the Newsletter of Department of Orthopedics, MIMER Medical College - **The Osteon**. It is aimed to serve as a platform for all the students and faculty to share their experiences and opinions related to various aspects of Orthopedics. It will also be a mean to showcase the various happenings in the department which may not necessarily be of only clinical and academic nature.*

*The contributors can share their and that of their colleagues, various extracurricular events, personal achievements, interesting events, artistic compositions etc. It will also be a source to get updated about the important news and significant happenings in the field of Orthopedics, in and around the region. We hope that it will interest readers and add new dimensions to their thought process.*

*I, on the behalf of Department of Orthopedics, offer my best wishes to the entire editorial team.*

**Dr Santosh Borkar**

Professor & Head, Department  
of Orthopedics



## TEAM ORTHO MIMER

|  |   |
|--|---|
| Dr Darpan Maheshgauri (Professor and Medical Superintendent) | Dr Abhinav Prabhu (Junior Resident)     |
| Dr Santosh Borkar (Professor and Head of department)         | Dr Shubham Nagre (Junior Resident)      |
| Dr Prasanth Kamath (Professor and Head of Unit III)          | Dr Nikhil Kulkarni (Junior Resident)    |
| Dr Shivraj Konde (Professor)                                 | Dr Ankit Gangreddiwar (Junior Resident) |
| Dr Manas Pusalkar (Associate Professor)                      | Dr Nikhil Phatale (Junior Resident)     |
| Dr Rajeev Munde (Assistant Professor)                        | Dr Govind Tidke (Junior Resident)       |
| Dr Himanshu Bishnoi (Assistant Professor)                    | Dr Rahul Ravariya (Junior Resident)     |
| Dr Ashwin Madavi (Senior Resident)                           | Dr Shubham Chaudhari (Junior Resident)  |
| Dr Suraj Doshi (Senior Resident)                             | Dr Jayesh Shirsat (Junior Resident)     |
| Dr Sandesh Kurlle (Senior Resident)                          | Dr. Bhargav Sutar (Junior Resident)     |
|  | Dr. Sameed Ahmed (Junior Resident)      |
|  | Dr Bhushan Adhari (Junior Resident)     |

Dr Animesh Gunjal

Dr Vipul Pise

Dr Rhythm Tahilramaney

Dr Shubham Sanap

Dr Kairav Purohit

Dr Aditya Harip

**Our department is excited and waiting for new PG junior residents to join our team at MIMER !**




## Some Interesting Cases

In this year, there was a surge in the trauma cases and some interesting fractures and ligamentous injuries presented to the hospital and were real additions to this learning experience

## Gavriil Ilizarov

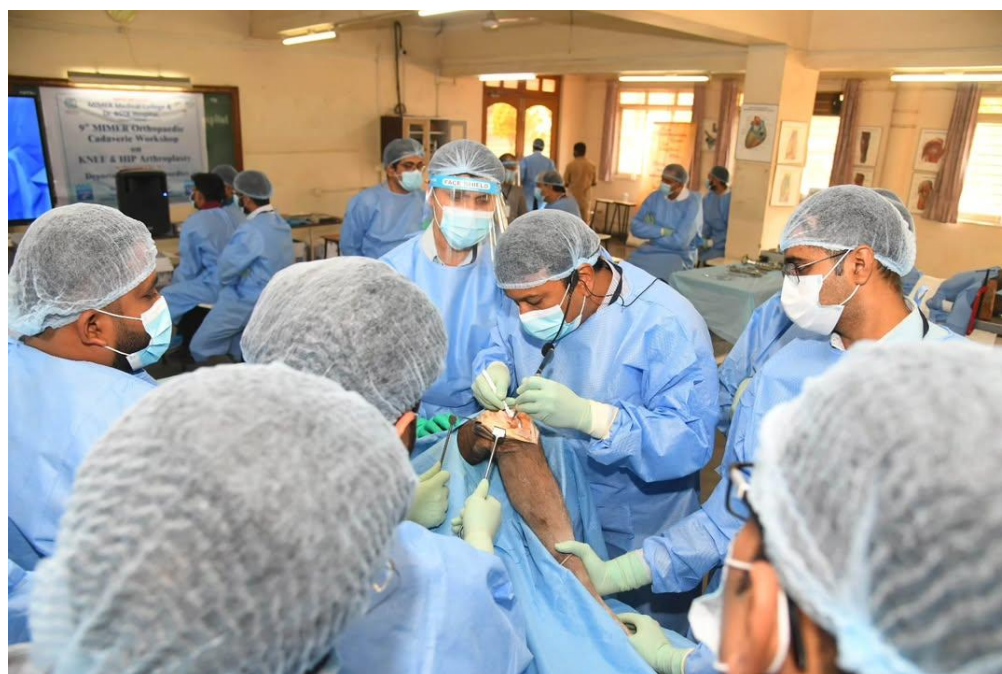### *The Magician from Kurgan*

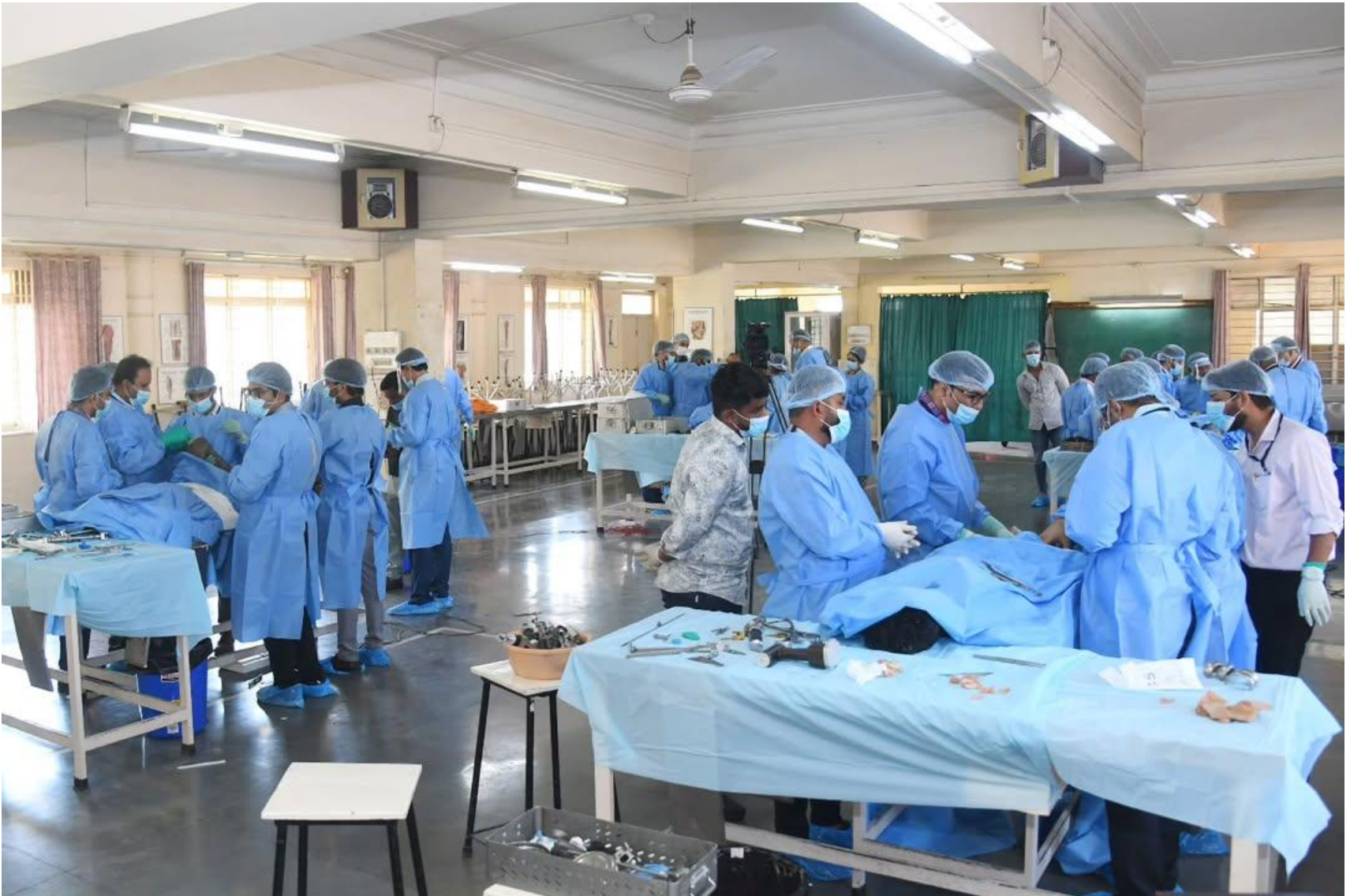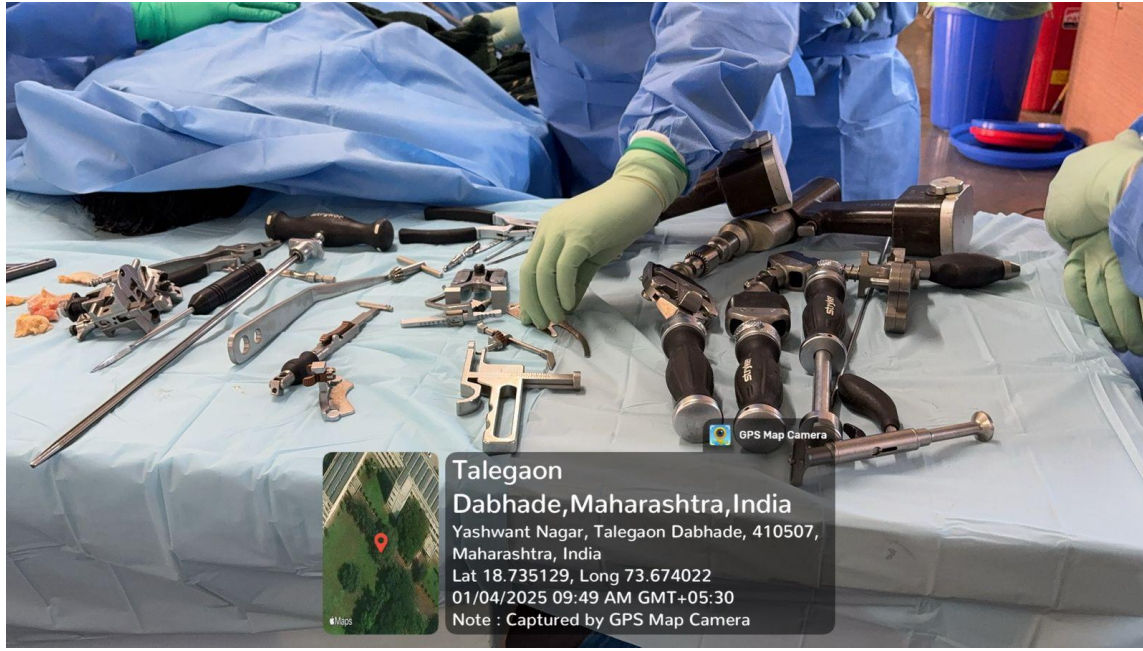
Methodological solutions of Prof. G.A. Ilizarov are the core stone of the contemporary bone lengthening and reconstruction surgery. They have been acknowledged in the orthopedic world as one of the greatest contributions to treating bone pathologies. The Ilizarov method of transosseous compression–distraction osteosynthesis has been widely used for managing bone non-union and defects, bone infection, congenital and posttraumatic limb length discrepancies, hand and foot disorders. The optimal conditions for implementing distraction and compression osteogenesis were proven by numerous experimental studies that Prof. G.A. Ilizarov organized and supervised at a large orthopaedic research institute in Kurgan. The impact of the Ilizarov method on the progress of bone lengthening and reconstruction surgery could be called revolutionary.



# CADAVERIC WORKSHOP ON HIP & KNEE ARTHROPLASTY

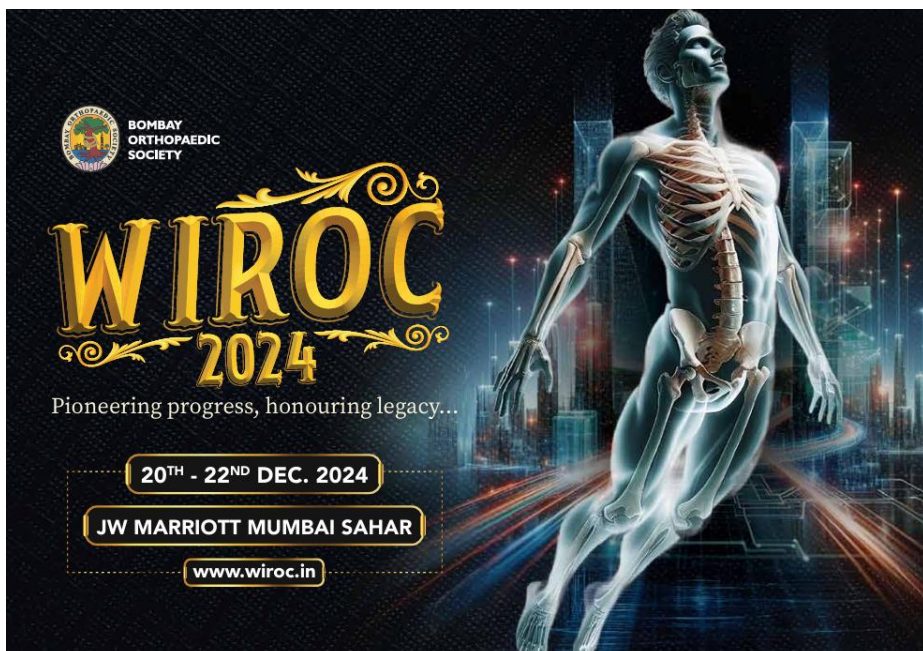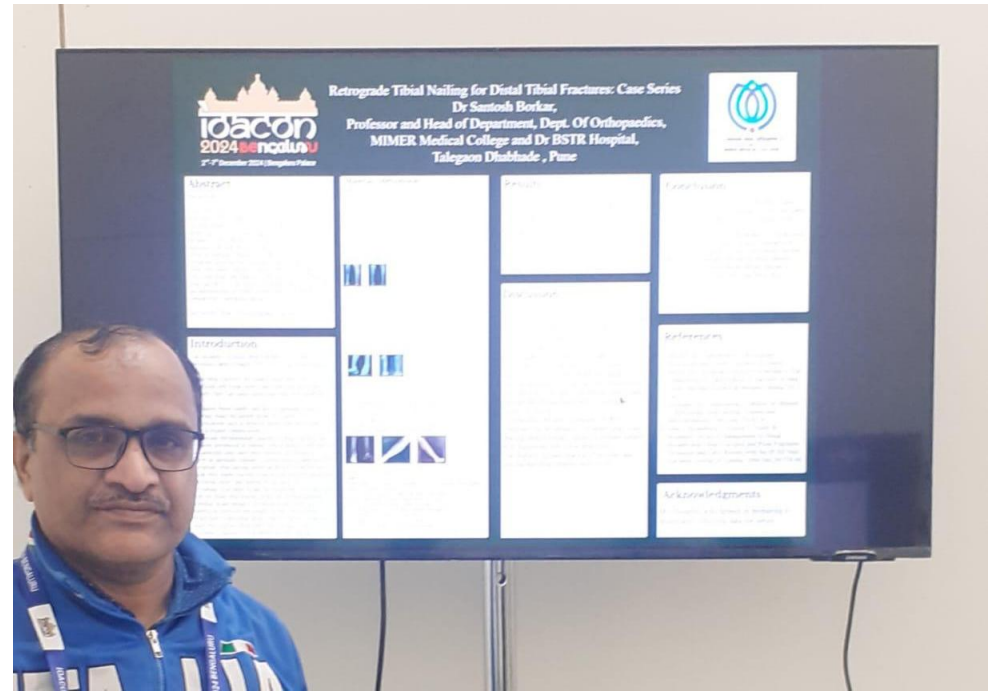
The 9<sup>th</sup> MIMER Orthopaedic Cadaveric workshop on hip & Knee Arthroplasty was conducted by department of Orthopaedics on January 4, 2025 in collaboration with department of anatomy. The workshop featured 16 joint stations and was guided by distinguished arthroplasty faculty members from Pune & Mumbai, including Dr Umesh Nagare, Dr Suhas Kamble, Dr Roshan Wade, Dr Sarang Deore, Dr Sandip Birari, Dr Ashish Arbat, Dr Vishal Patil, Dr Hemant Patil. During the workshop, the basic steps & finer nuances of Total hip replacement surgeries were demonstrated, offering participants a comprehensive learning experience. The event saw active participation from Orthopaedic surgeons & postgraduate students from various parts of the state. The workshop received enthusiastic feedback from delegates, who praised the hands-on experience, availability of diverse arthroplasty systems, and the excellent knowledge & expertise shared by the facilitators.





# ALL ABOUT CONFERENCES

Dr Santosh Borkar participated as a delegate in PG teaching program and also presented poster at 69<sup>th</sup> Annual Conference of Indian Orthopaedic Association (IOACON) 2024 held from 2<sup>nd</sup> to 7<sup>th</sup> December 2024 at Bengaluru



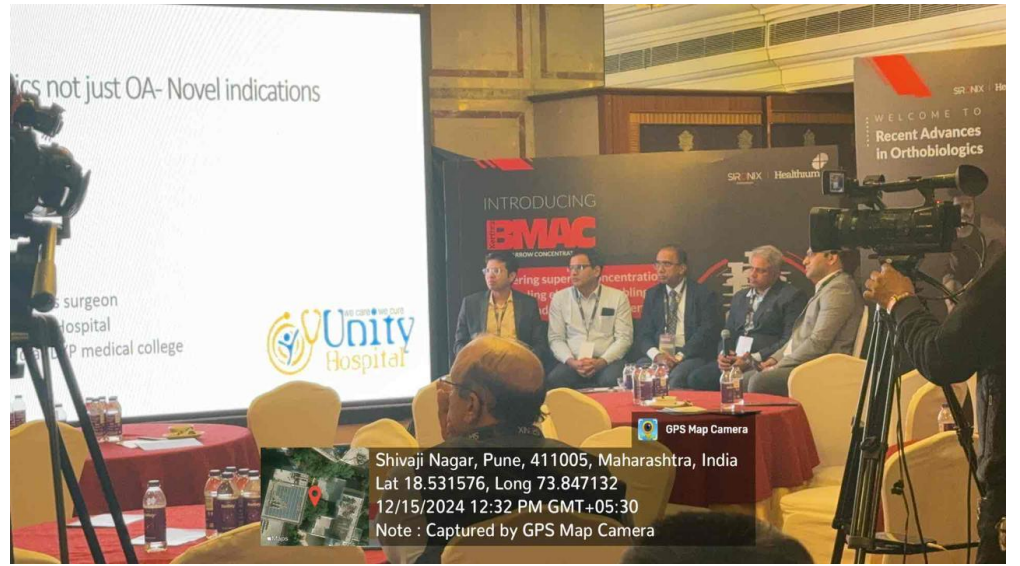Dr Shivraj Konde and Dr Manas Pusalkar attended & participated as a delegate at WIROC 2024 held at JW Marriott Sahar ,Mumbai from 20<sup>th</sup> to 22<sup>nd</sup> December 2024.

Dr Shivraj Konde participated as a delegate at 11<sup>th</sup> TRAUMA CONCLAVE 2024-2025 held at Sahara star ,Mumbai from 17<sup>th</sup> & 18<sup>th</sup> January 2025.



Dr Rajiv Munde was invited as chairperson at Arthroscopy session & paper presentation session at WIROC 2024 held at JW Marriott Sahar ,Mumbai from 20<sup>th</sup> to 22<sup>nd</sup> December 2024

Dr Rajiv Munde was invited as a panelist for 'Orthobiologics not just OA ! Novel indications ' session at Recent advances in Orthobiologics held at Hotel Pride ,Shivajinagar on 15<sup>th</sup> December 2024.



Dr Rhythm Tahilramaney won first prize in scientific paper presentation at TIMACON 2024 held on 8<sup>th</sup> December 2024

Dr Manas Pusalkar , Dr Rahul Ravariya & Dr Shubham Chaudhari presented case presentations in Consultant & PG session respectively at Pune Orthopaedic Society Monthly Clinical meet January 2025 held at Jupiter Hospital ,Baner.

Dr Shubham Chaudhari won joint first prize in PG case presentation session .



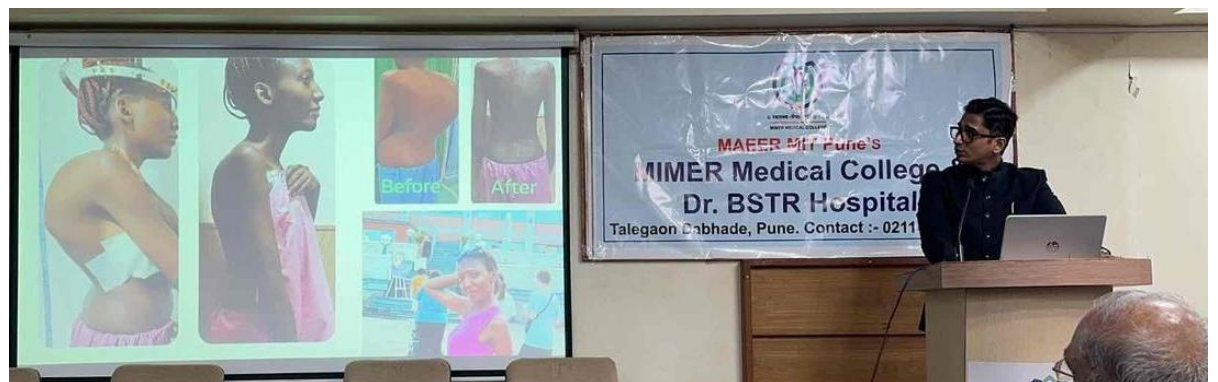
## ***GUEST LECTURES!***



The Department of Orthopedics organised a guest lecture, "**Role Of Robot in Hip And Knee Joint Replacement**" by Dr Suhas Kamble, Managing Director of Sainath Hospital, Moshi on 9th August 2024. The eminent speaker spoke elaborately about Robotic-Assisted Joint Replacement surgery using the advanced Mako Robot system and latest innovations in Orthopedic surgery highlighting how precision meets technology. This session provided all aspiring orthopaedic surgeons, resident trainees And physiotherapists a learning opportunity as well as a glimpse into the future of orthopedic surgery.



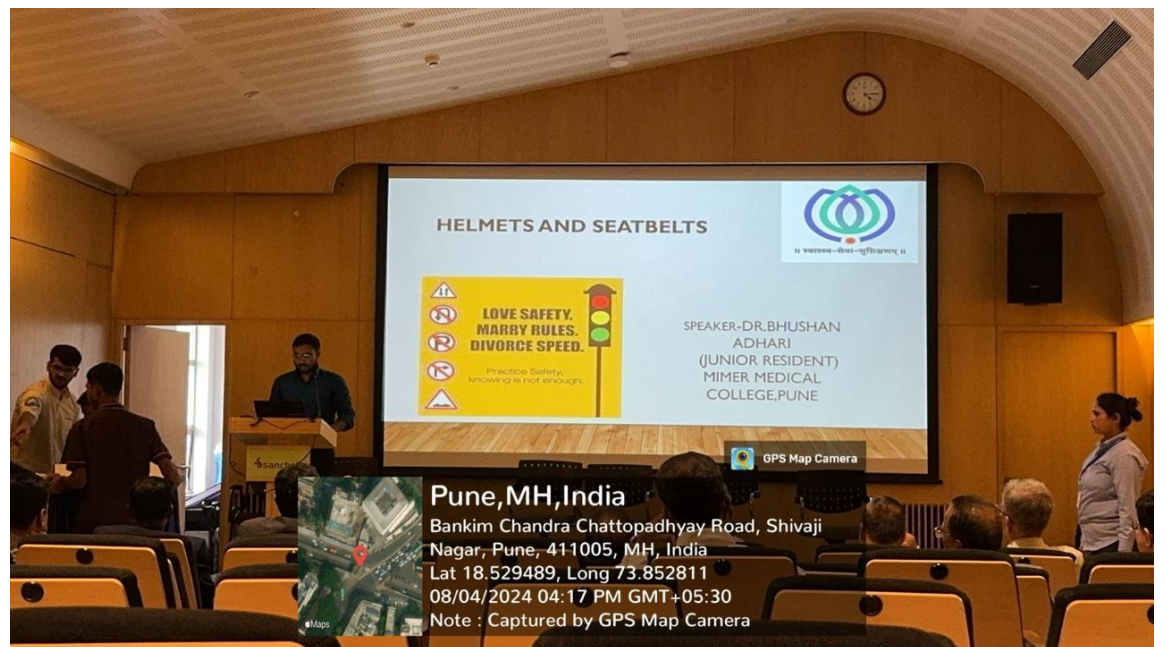ON THE OCCASION OF WORLD SPINE DAY, THE DEPARTMENT OF ORTHOPAEDICS ORGANIZED A GUEST LECTURE, "**MISCONCEPTIONS ABOUT SPINE DISEASES & RECENT ADVANCES IN TREATMENT**" BY DR. DHIRAJ SONAWANE, PROF. AND HEAD, ORTHOPAEDIC SPINE UNIT, GRANT GOVT. MEDICAL COLLEGE AND JJ GROUP OF HOSPITALS, MUMBAI. DR. DHIRAJ SONAWANE IS AN ALUMNUS OF MIMER- BATCH 1999.



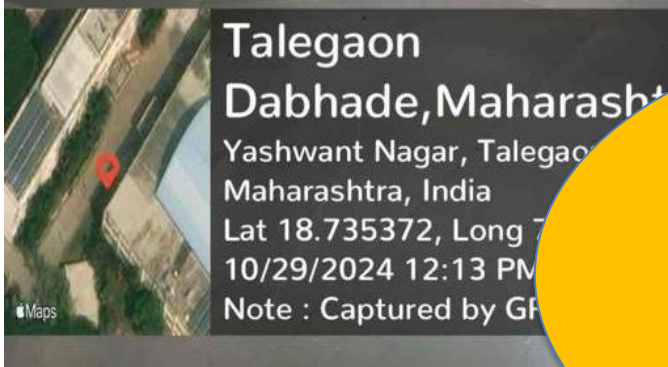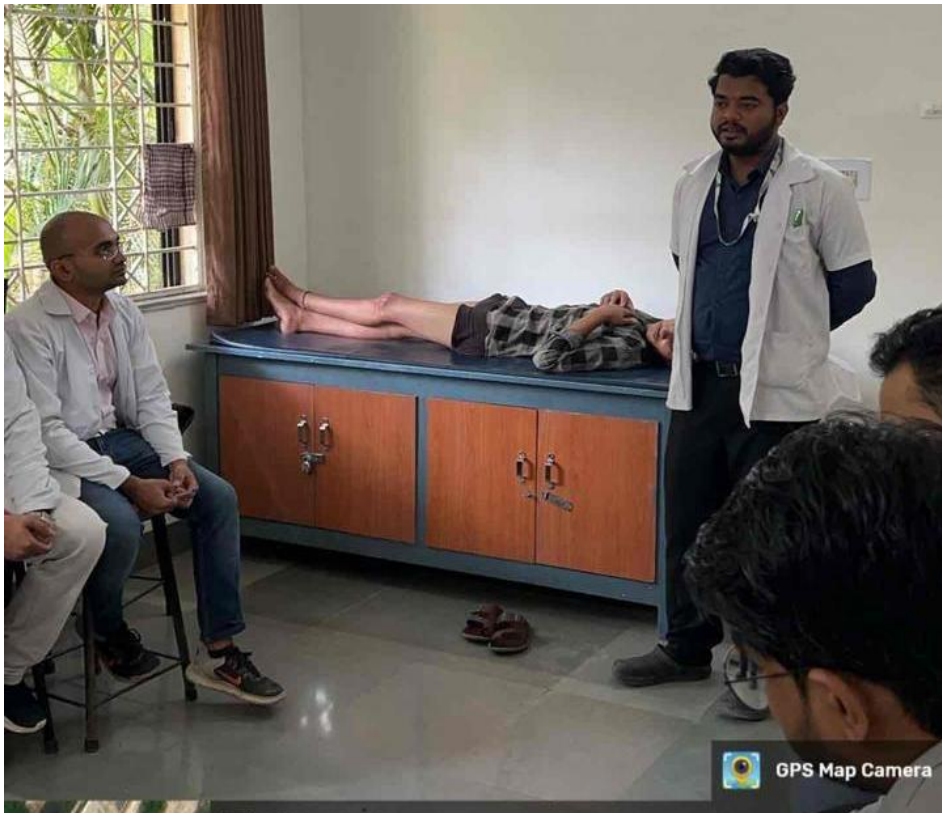ON THE OCCASION OF PAEDIATRIC BONE & JOINT DAY, THE DEPARTMENT OF ORTHOPAEDICS ORGANIZED A GUEST LECTURE, "COMMON ORTHOPAEDIC PROBLEMS IN CHILDREN" BY DR. GOWERDHAN INGALE ON 18<sup>TH</sup> OCT 2024. DR GOWERDHAN INGALE IS ALSO PRESIDENT OF PUNE ORTHOPAEDIC SOCIETY.



Dr Bhushan Adhari ,our 2<sup>nd</sup> year Junior resident presented a talk on **Road safety Awareness** on occasion of **Bone & Joint Day** ( 4<sup>th</sup> August 2024) at Sancheti Hospital , Pune.



# Academic PG activities

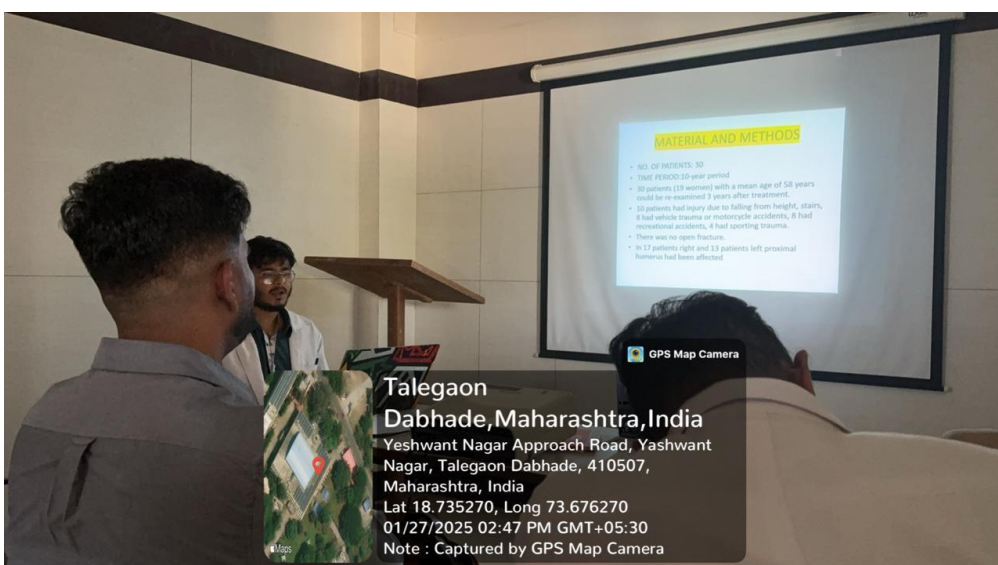

Talegaon  
Dabhade, Maharashtra  
Yashwant Nagar, Talegaon  
Maharashtra, India  
Lat 18.735372, Long 73.675662  
10/29/2024 12:13 PM  
Note : Captured by GPS Map Camera

**Case presentations !**



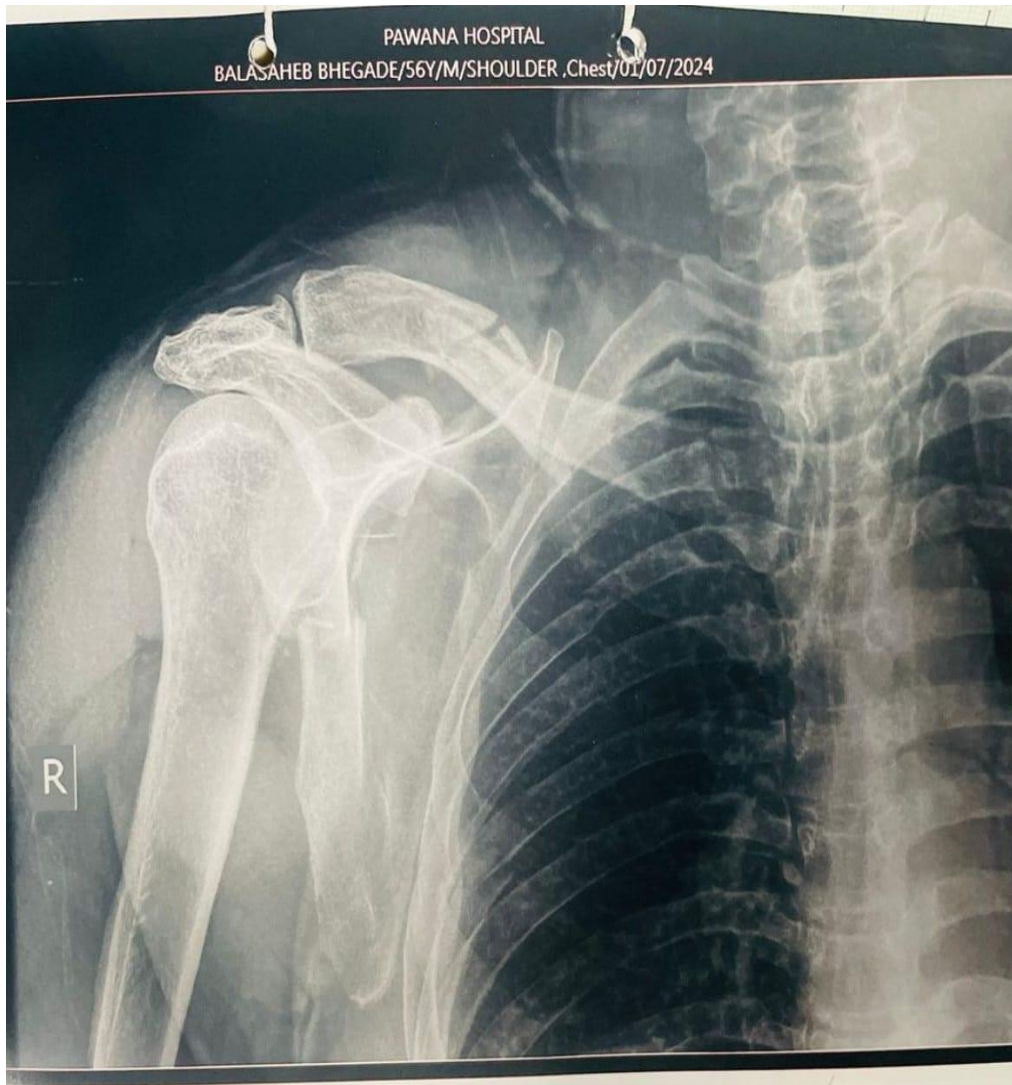Yashwant Nagar, Talegaon Dabhade, 410507,  
Maharashtra, India  
Lat 18.735270, Long 73.675662  
10/25/2025 12:21 PM GMT+05:30  
Note : Captured by GPS Map Camera



Talegaon  
Dabhade, Maharashtra, India  
Yashwant Nagar Approach Road, Yashwant  
Nagar, Talegaon Dabhade, 410507,  
Maharashtra, India  
Lat 18.735270, Long 73.676270  
01/27/2025 02:47 PM GMT+05:30  
Note : Captured by GPS Map Camera

**Journal club**

## TRAUMA SERIES



A 55 yr old male was brought to casualty by relatives with A/H/O RTA due to dash by 4 wheeler at Somatane phata on 1/07/24 at around 8:30pm.

C/o wound over head, right shoulder, left hand and left elbow since then.

No H/O head injury / LOC / ENT bleed / nausea / vomiting

No H/O any co-morbidities

O/E :

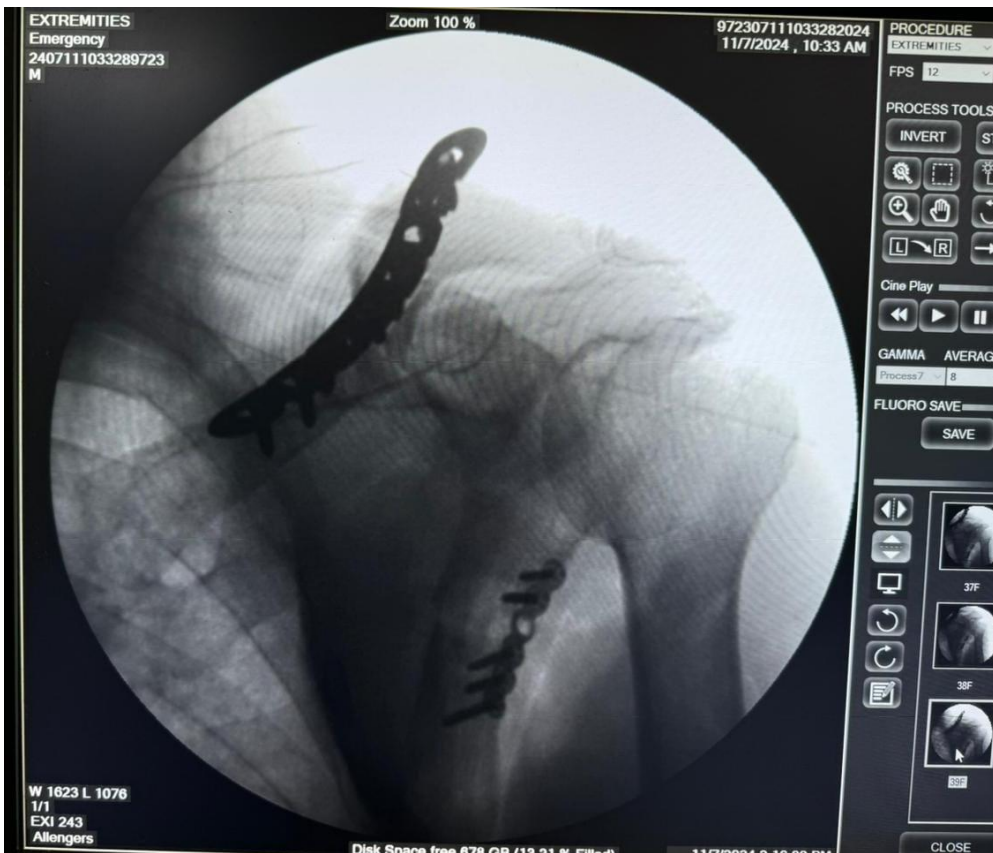
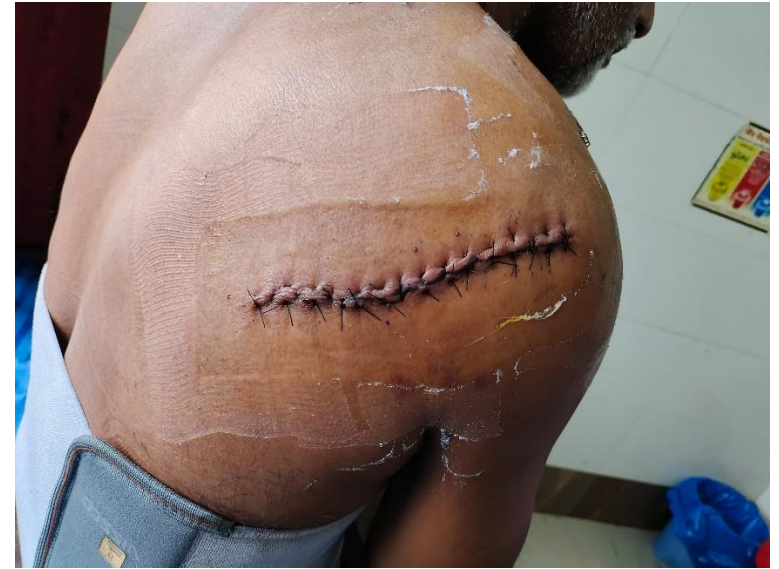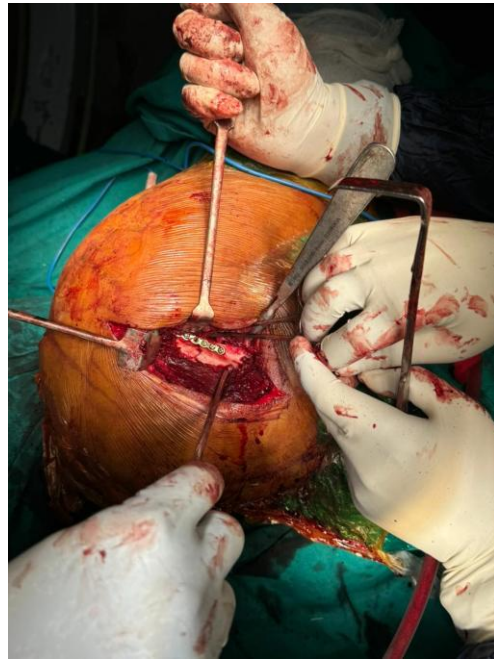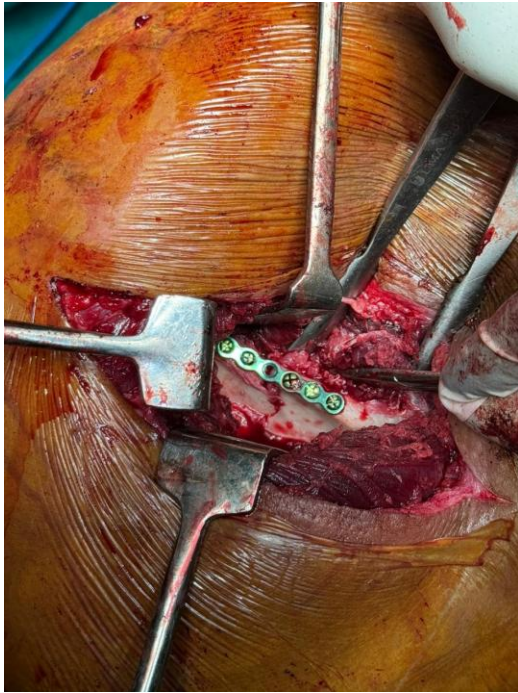
- 1) Multiple abrasions present over Right shoulder, Right elbow and left hand largest of size 10 x 4 cm.
- 2) Tenderness and swelling over right clavicle region and right side rib cage (2nd, 6th)
- 3) ROM at right shoulder painful and restricted.
- 4) Active wrist and finger movements present.
- 5) Sensation intact
- 6) Distal pulses palpable
- 7) Capillary refill normal
- 8) Chest compression test positive

### IMPRESSION:

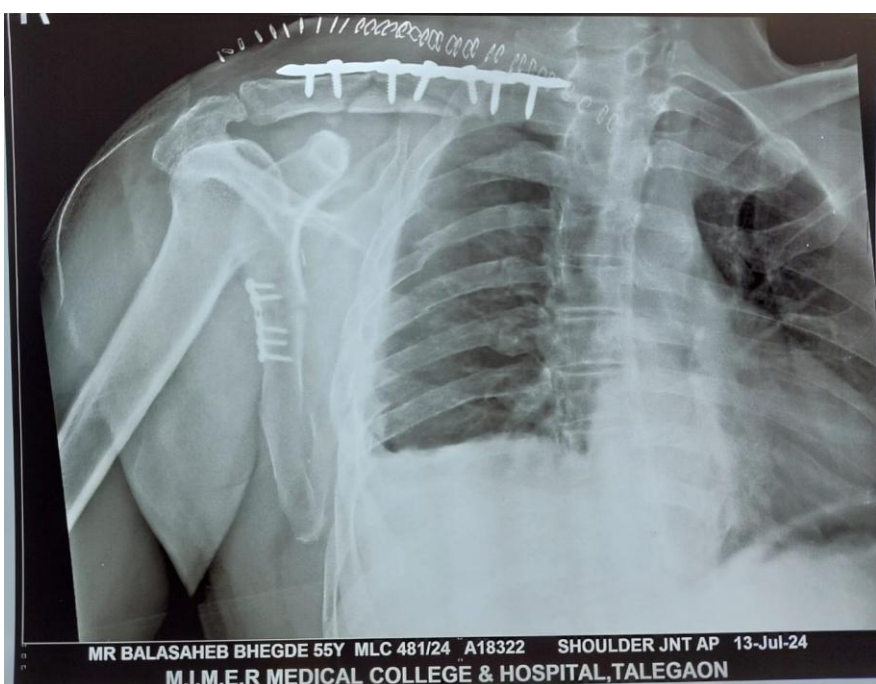
- Displaced comminuted overlapping Fracture of right scapular body below scapular spine seen.
- Displaced comminuted overlapping Fracture of mid right clavicular shaft, 6<sup>th</sup> 7<sup>th</sup> 4<sup>th</sup> and 5<sup>th</sup> mild posterior rib fracture also seen.
- Mild right side pleural effusion with mild underlying lung contusion seen.
- Mild upper lobe pneumothorax seen in right side with max width of 1.7 cm.

*Patient was operated with Open reduction and internal fixation with reconstruction plating for scapula # and open reduction and internal fixation with plating for clavicle*

Intra-op images



Intra-op x-ray



Post op x-ray

**A case of floating knee**

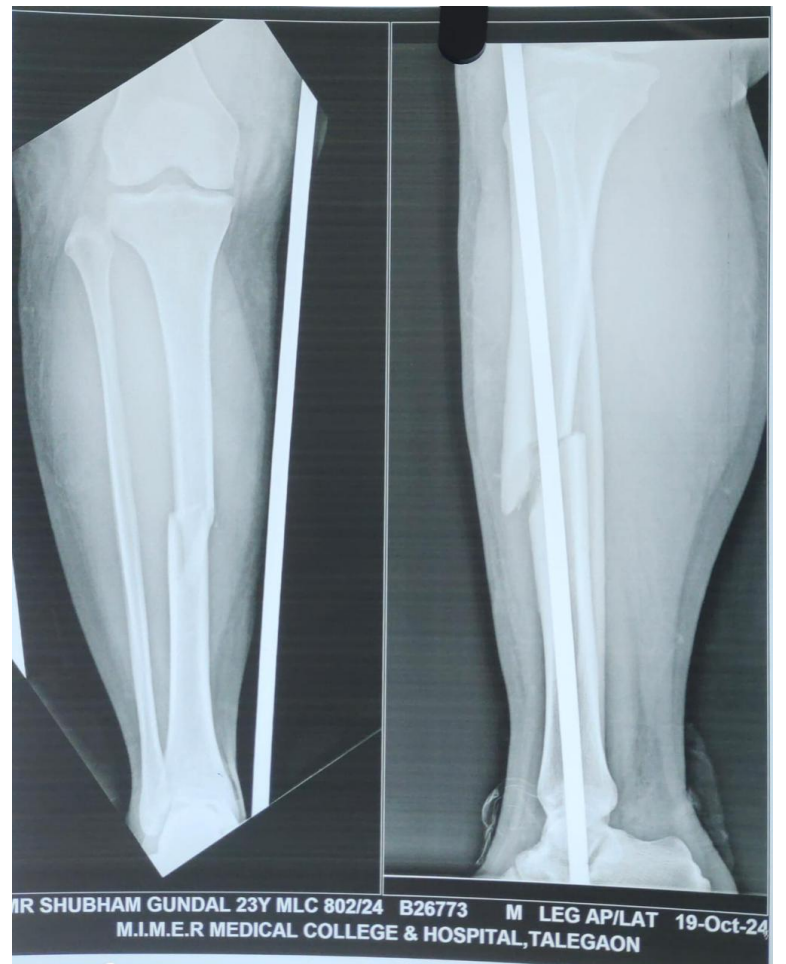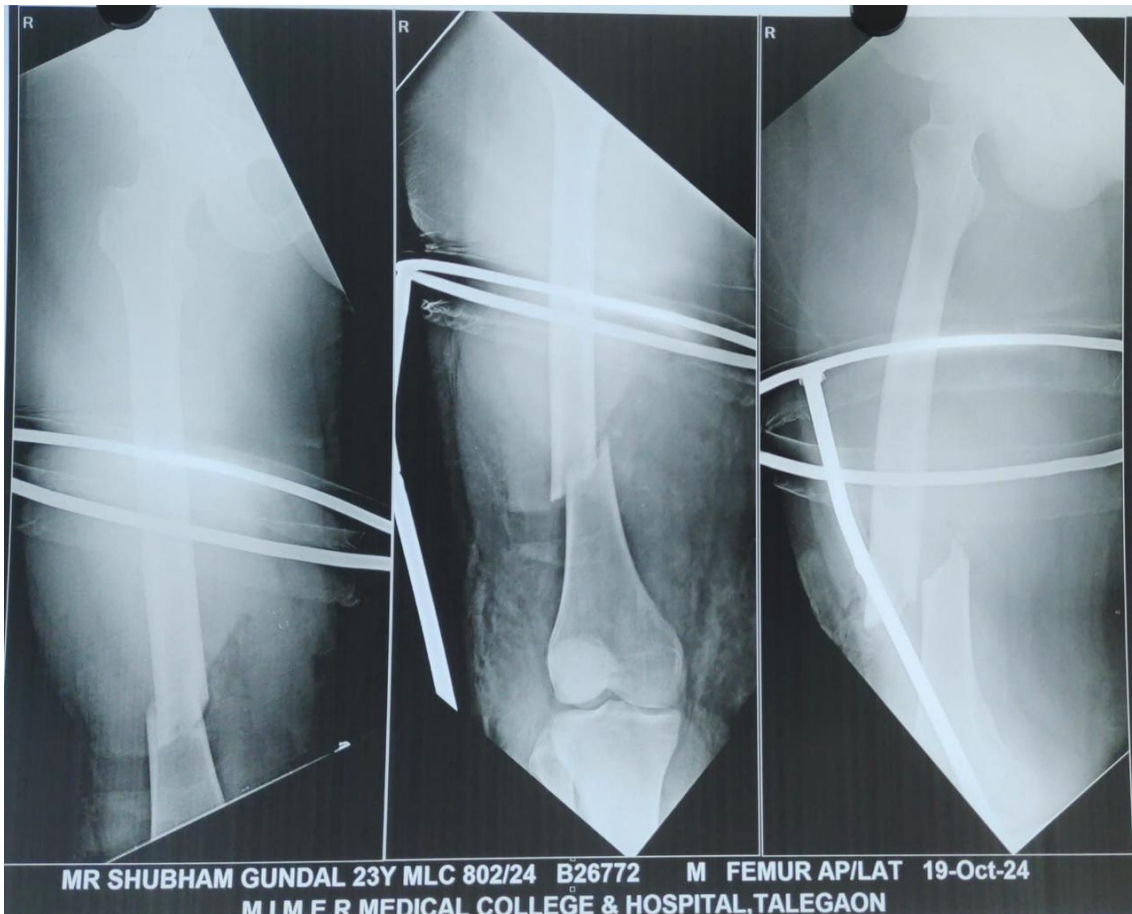
A 23yr old male brought to casualty by relatives with A/H/O RTA dash by bus while patient was on two-wheeler near dhanvantari hospital, talegoan - chakan road on 18/10/24 at around 11pm

C/o wound over right thigh , right leg , left eyebrow  
Pain and swelling over right thigh and right leg since then

No h/o head trauma /vomiting/ent bleed / seizures  
No h/o any known co morbidities

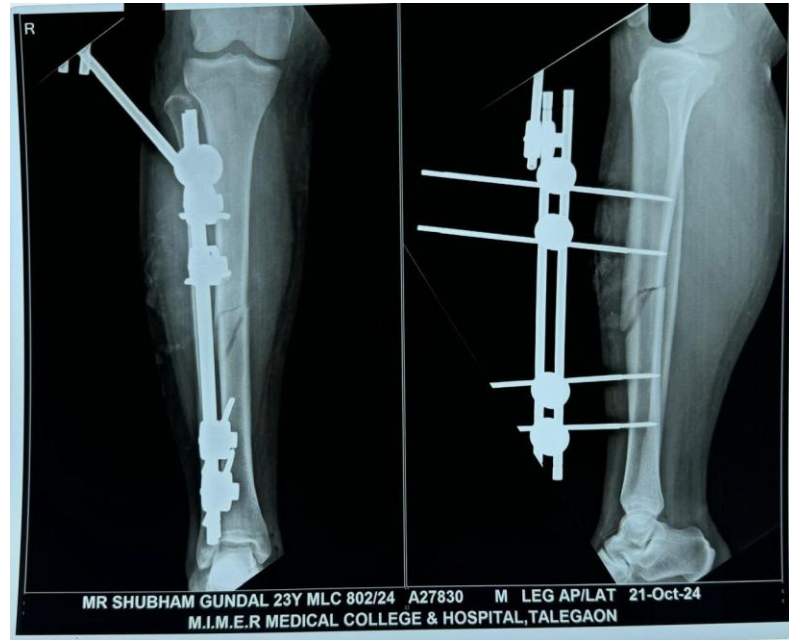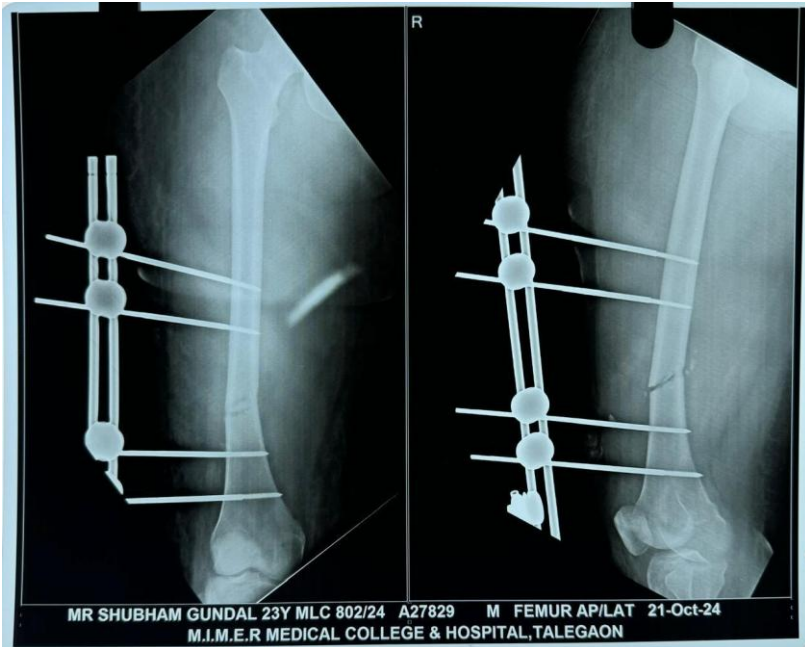
O/E :

- 1)CLW present over left eyebrow of size 3.5x1.5x2cm
- CLW present over right midshaft femur region of size approx 8x4x3cm
- CLW present over posterior aspect of right ankle of size approx 4x1x1cm
- 2) Abrasion present over right tibia of size approx 2x1cm
- Abrasion present over right eyebrow of size approx 1.5cm x1cm
- Abrasion present over right knee of size approx 1x2cm
- Abrasion present over left little toe of size approx 1x1cm
- 3) Swelling and tenderness present over right midshaft femur and tibia region
- 4) ROM at right hip, right knee and right ankle painful and restricted.
- 5) Active toe movements present
- 6) distal pulses palpable
- 7) Sensation intact
- 8) capillary refill normal
- 9) No spinal/calcaneal tenderness
- 10) Chest / pelvic compression test negative

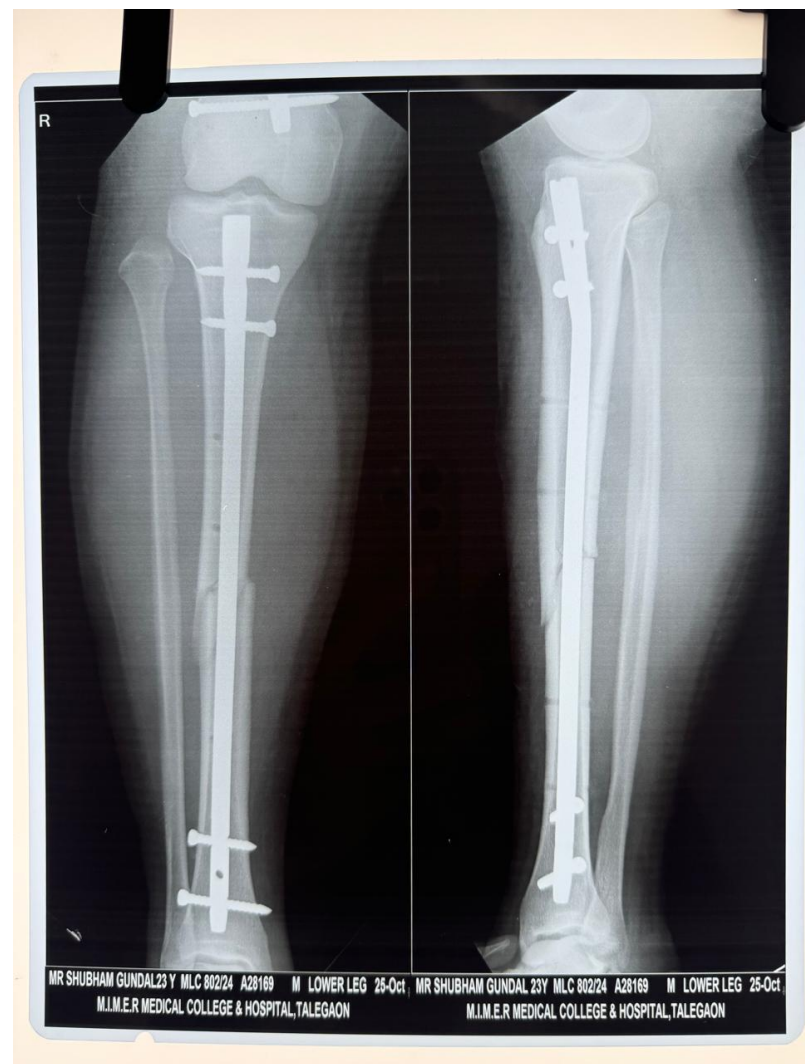
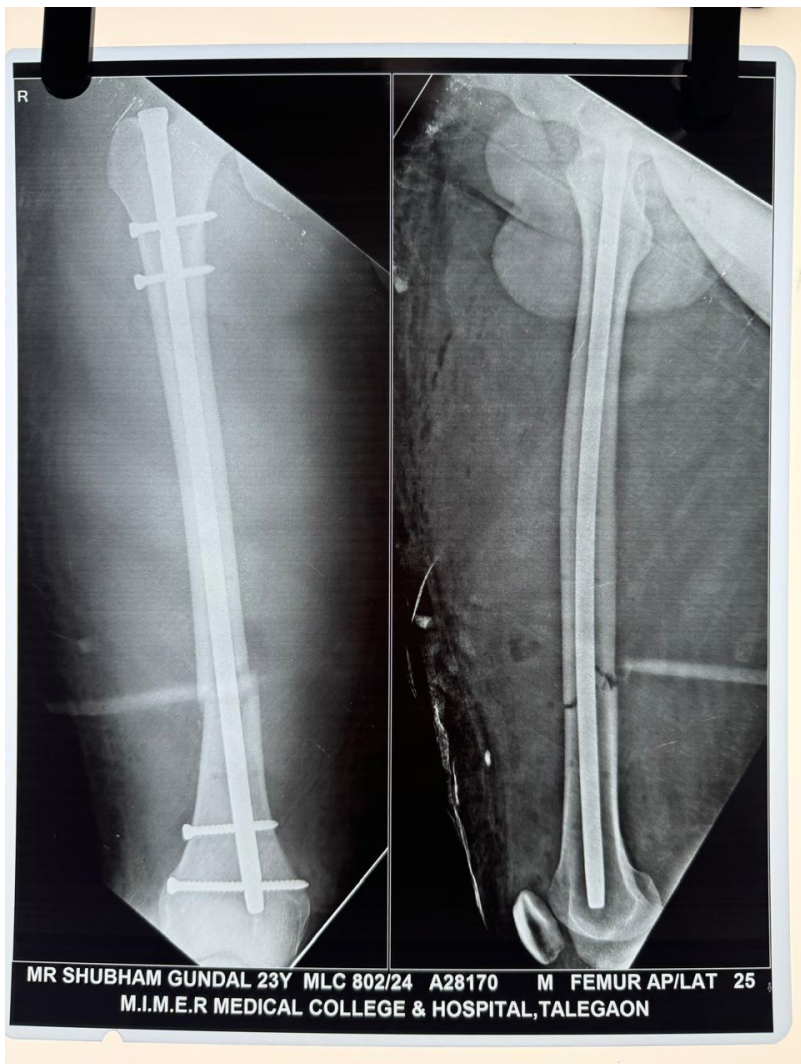
**SURGERY:**

Stage 1 surgery was performed for provisional fixation with Debridement & Closed Reduction with External fixator application for shaft femur & shaft tibia fracture.



Stage 2 surgery was performed with definitive fixation using intramedullary interlocking nailing for tibia and femur.



A 10yr old male was brought to the OPD by relative with

C/o ? Pain and swelling over the back since 1 year

No H/O any fall or trauma

No h/o any known co morbidities

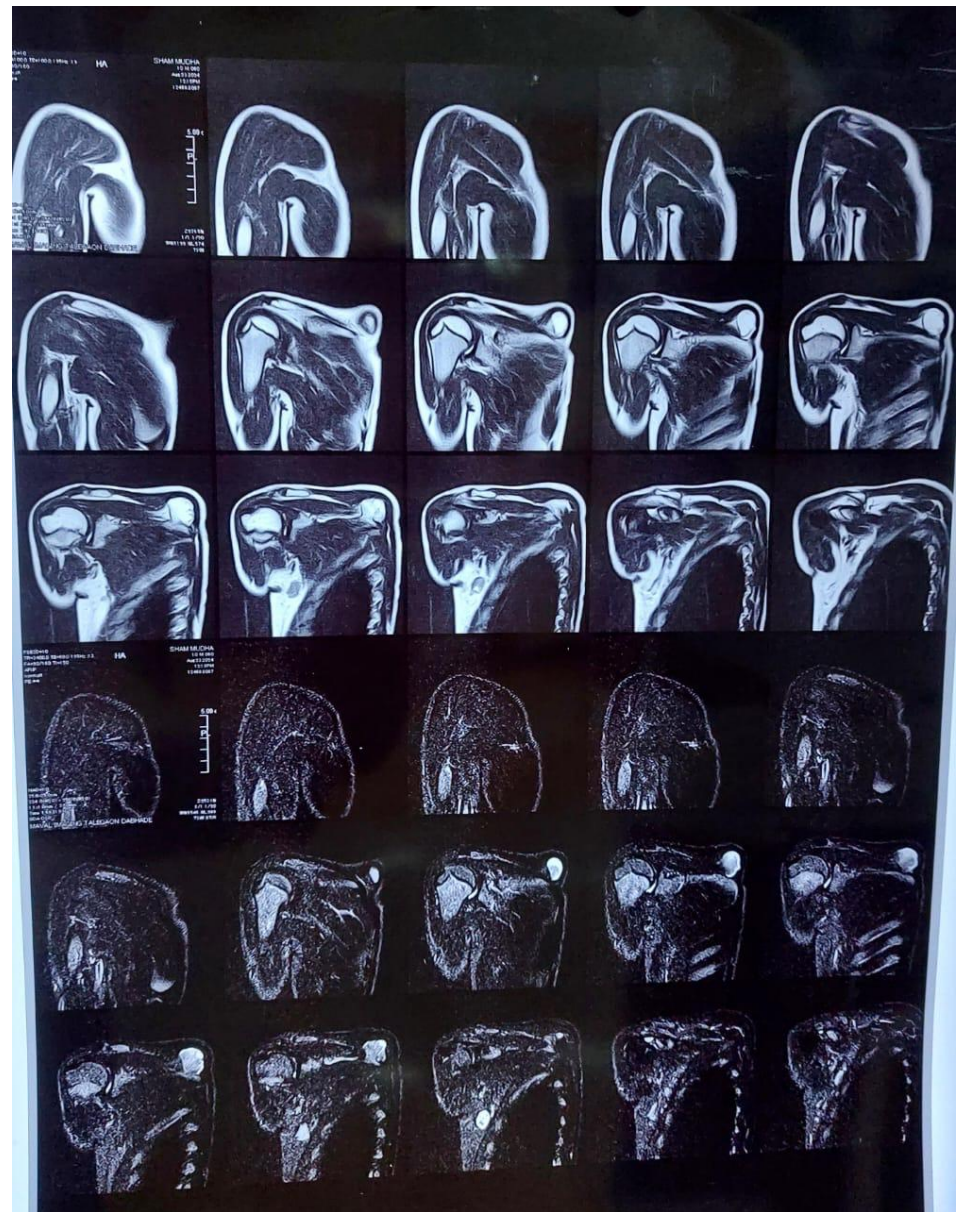
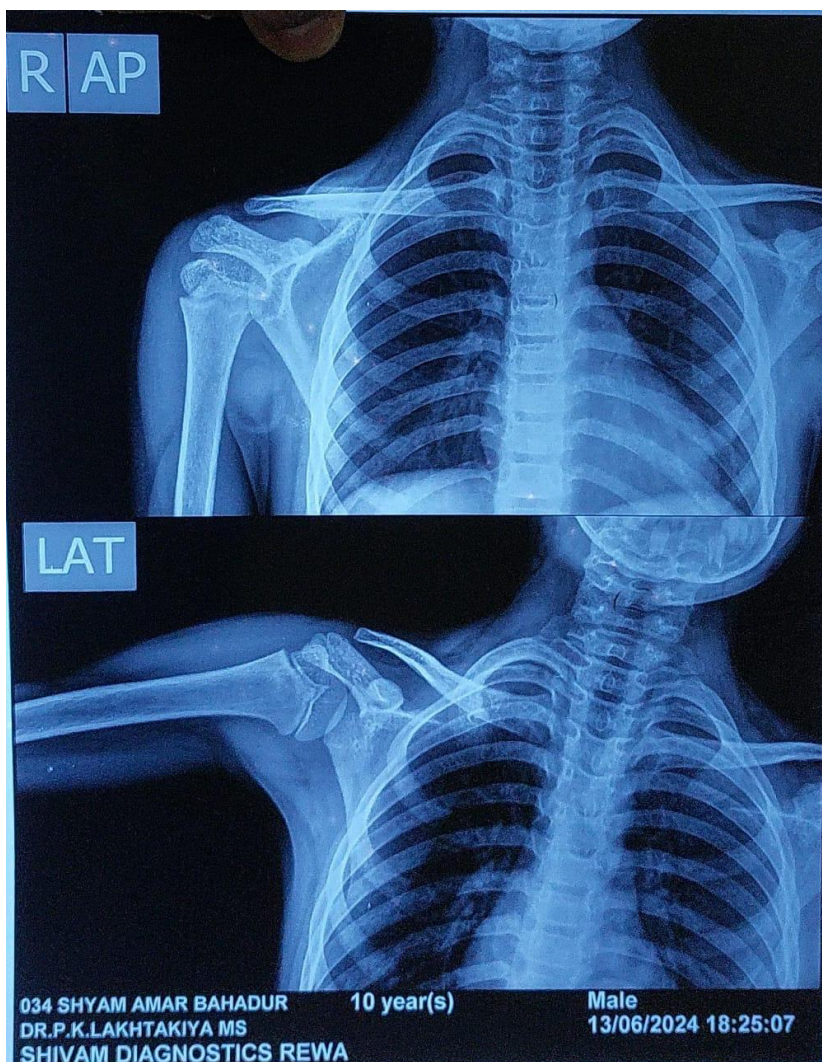
G/e :

Gc fair

P - 88/min

O/E :

- 1) Bony hard swelling arising from Right scapula seen
- 2) ROM at right shoulder full and painless
- 3) Active wrist and finger movement present.
- 4) Sensation intact
- 5) Distal pulses palpable

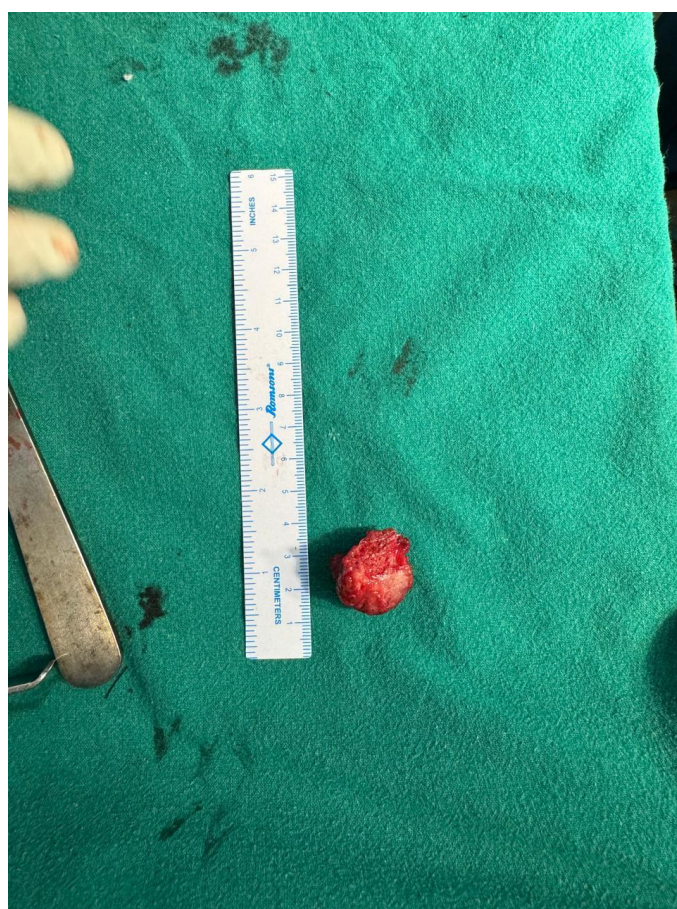
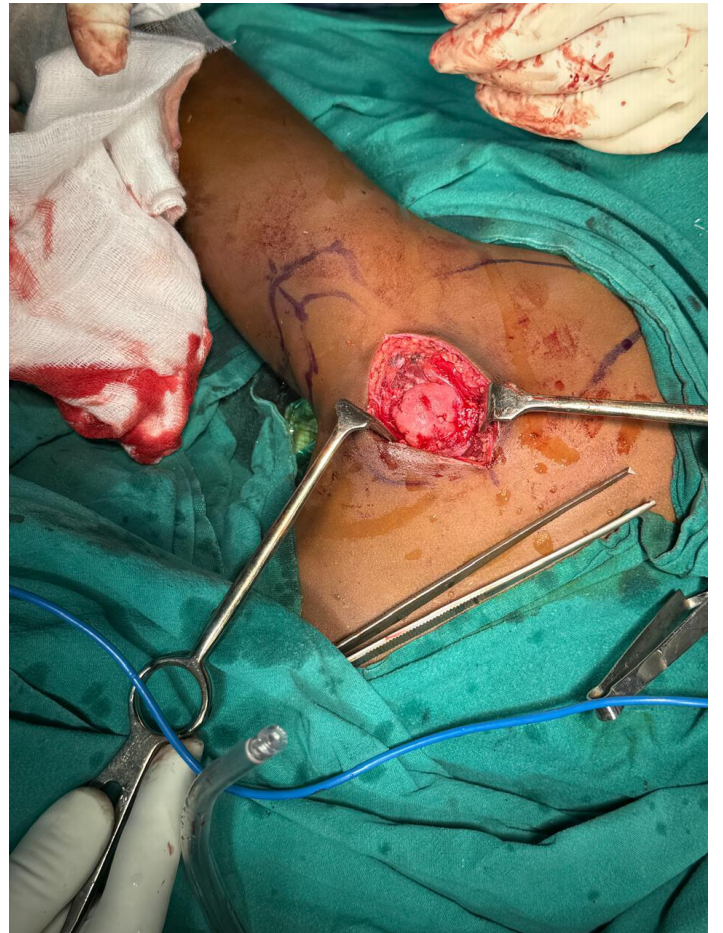
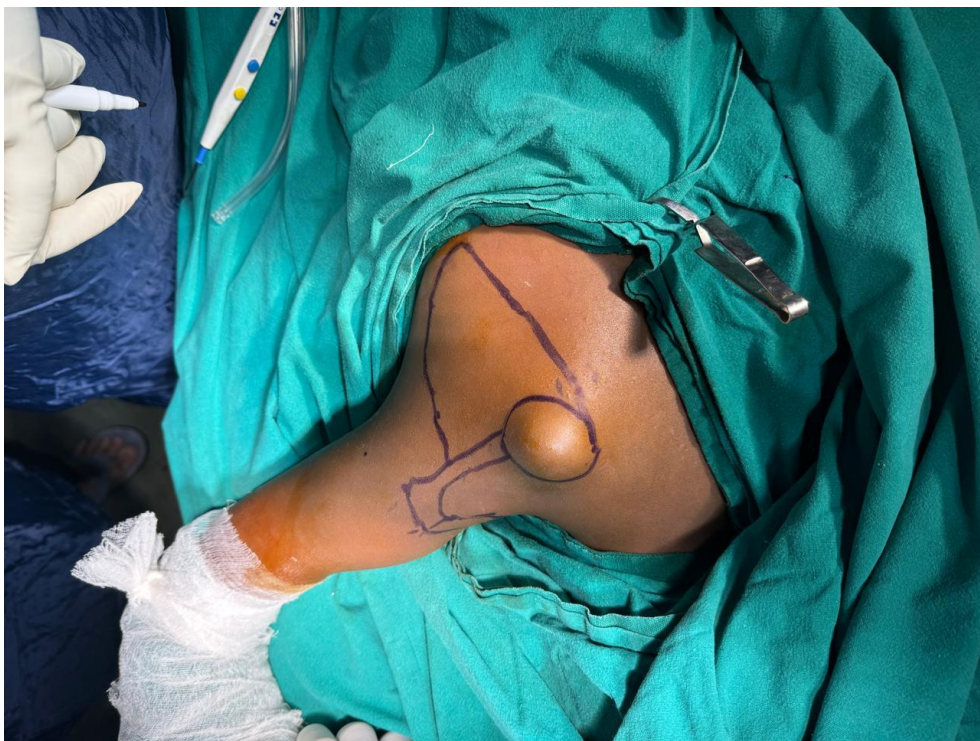---

*Patient was operated with excision*

---

Intra op images



**A CASE OF LEFT TENDOACHILLES TEAR**

A 66yr old male came to casualty brought by relatives A/H/O twisting injury to left ankle while working

in farm, khed on 15/8/24 at around 12:30pm

C/O pain and swelling over left leg since then

No h/o head trauma/LOC/ENT bleed /vomiting/seizure

No h/o any known co morbidities

G/e :

Gc fair

P - 86/min

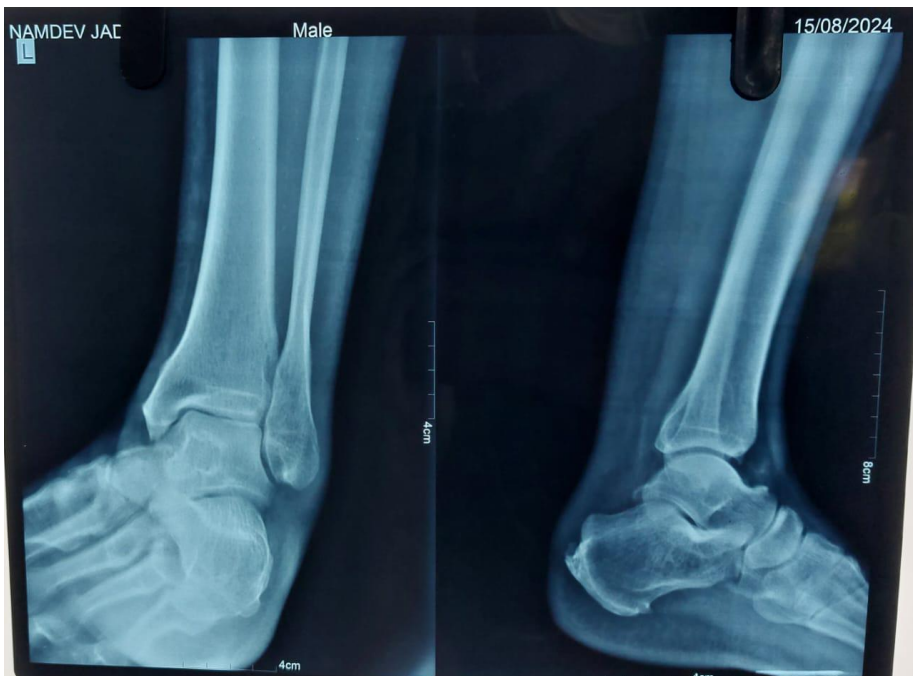Bp - 130/70mmhg

SpO2 - 98% on RA

O/E :

- 1) Swelling and tenderness present over posterior aspect of left ankle
- 3) Rom at left ankle - painful and restricted (dorsiflexion and plantarflexion)
- 4) Active toe movement present
- 5) Sensation intact
- 6) Distal pulses palpable
- 7) Capillary refill normal
- 8) no Spinal / calcaneal tenderness
- 9) Thompson test - positive

B/K slab given in plantar flexion

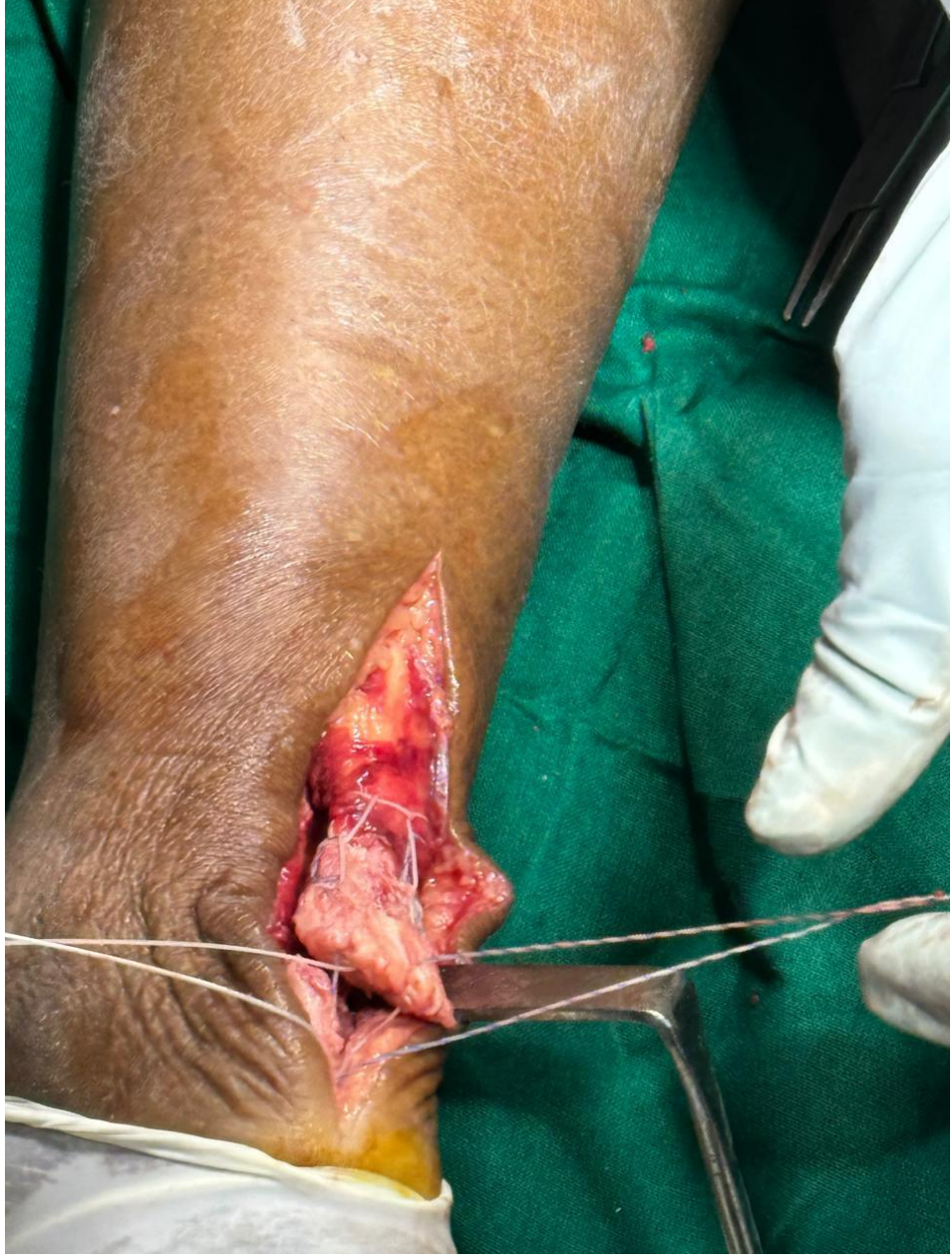
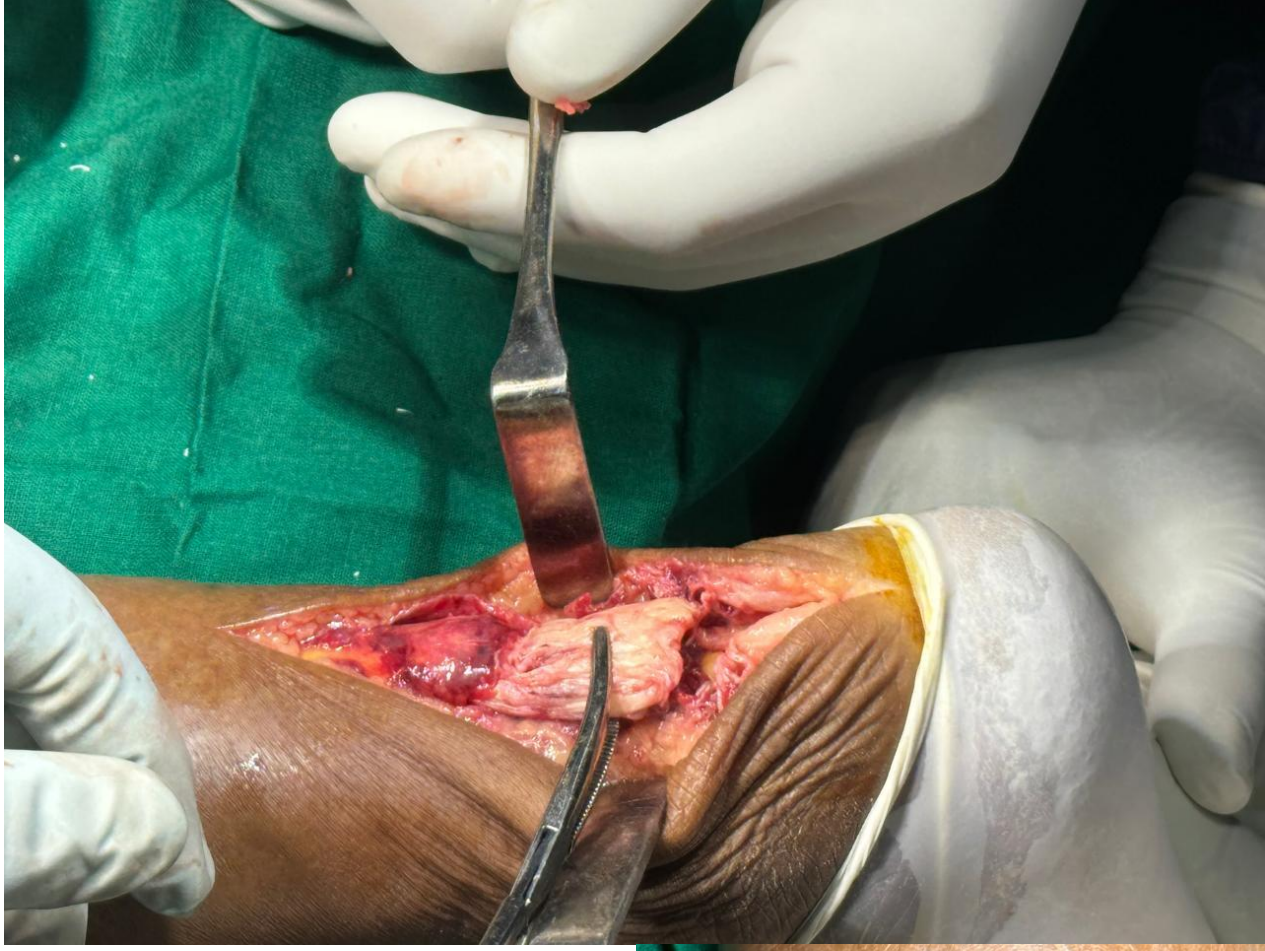
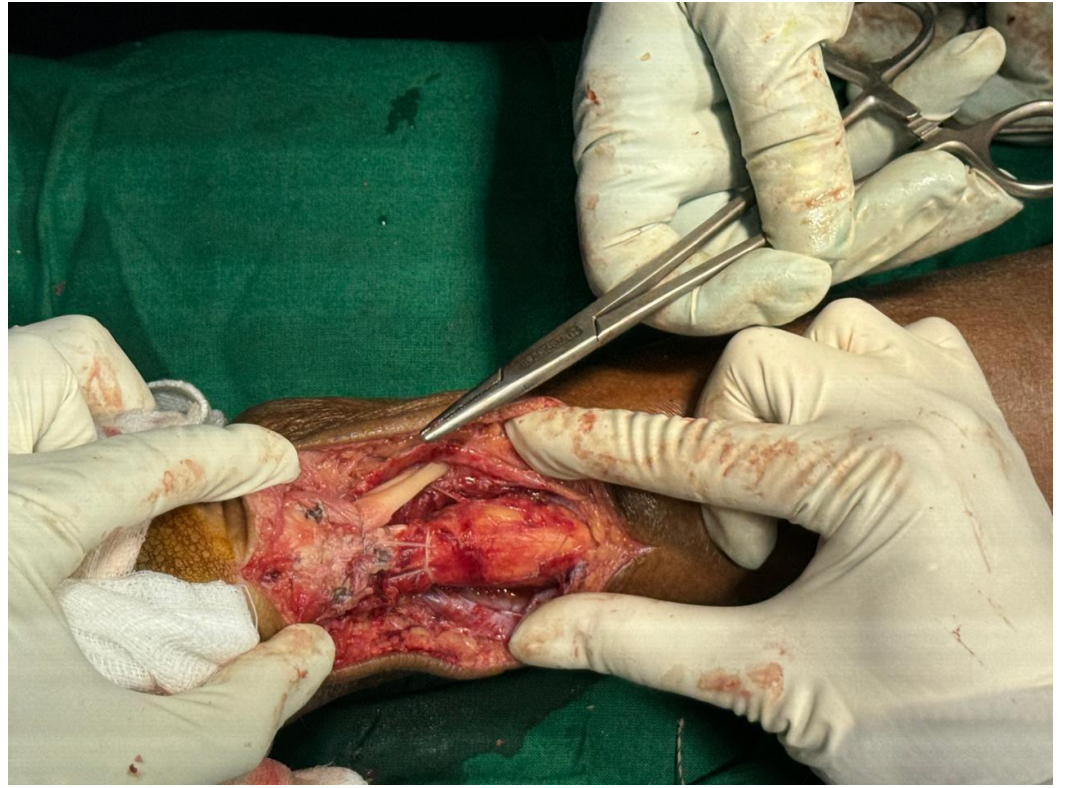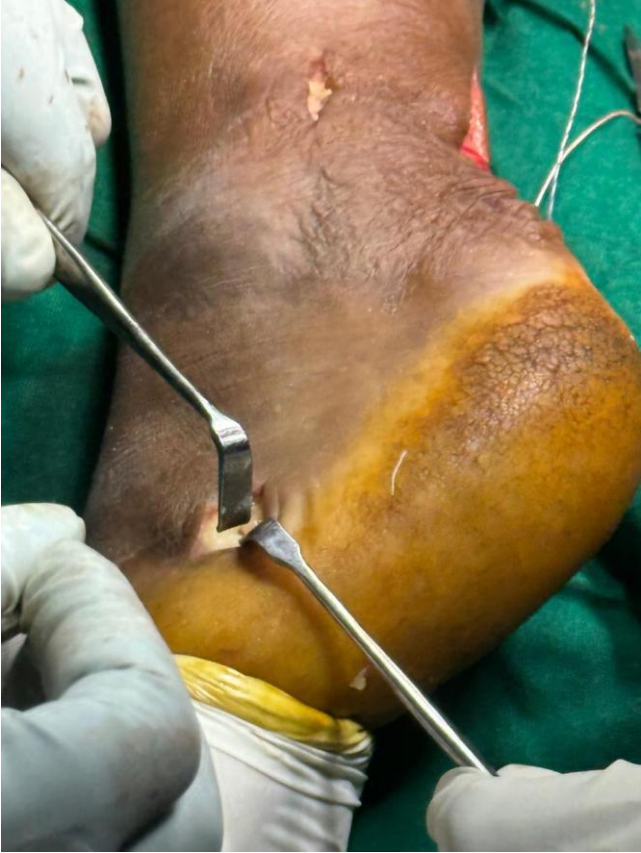---

*Patient was operated with tendoachilles repair with fibre wire & peroneus brevis augmentation*

---

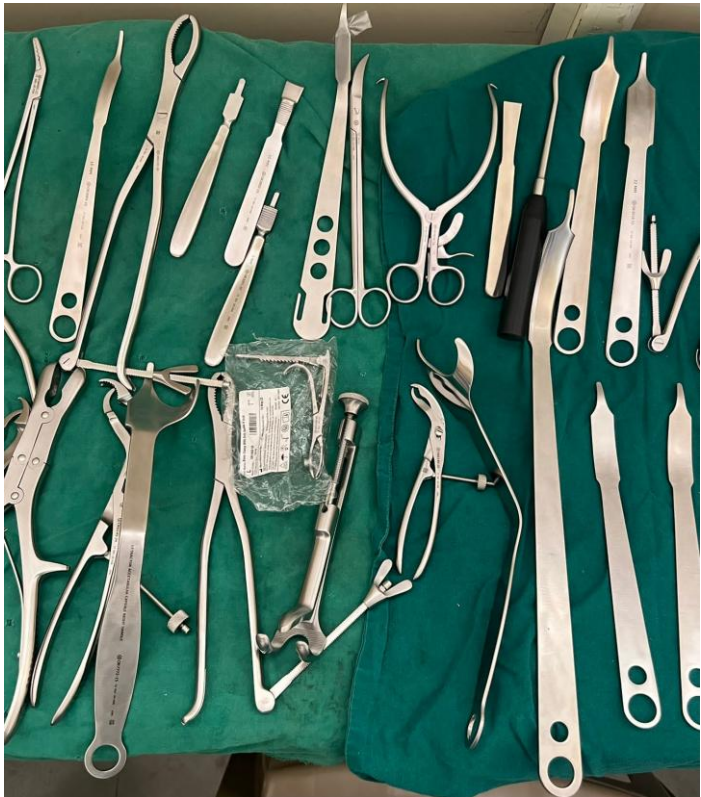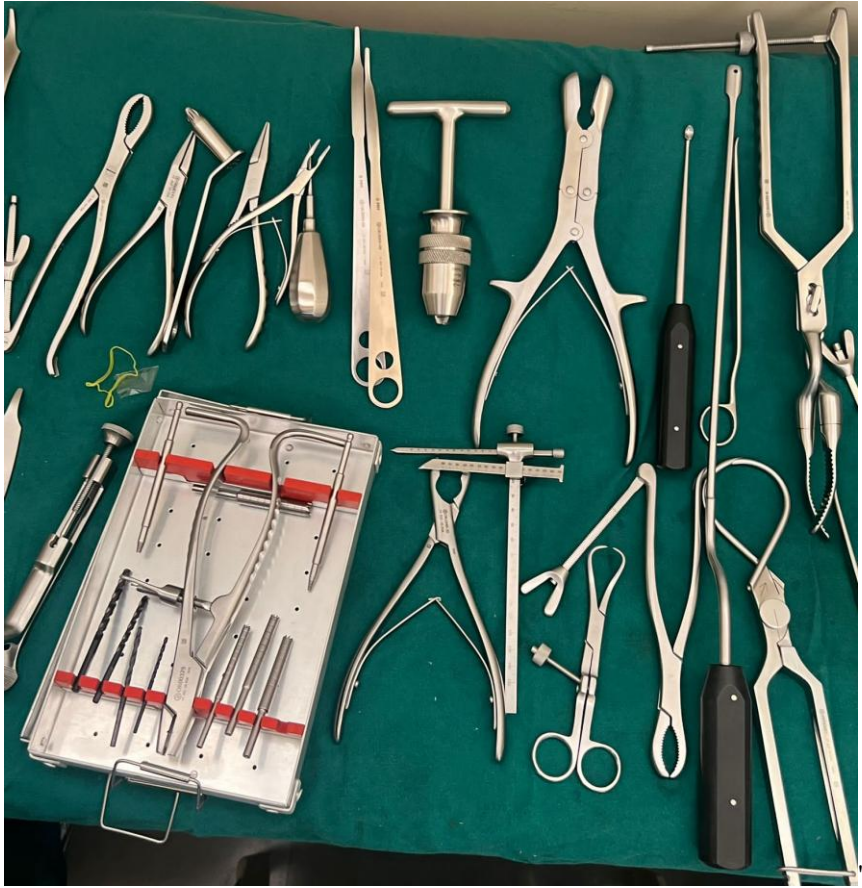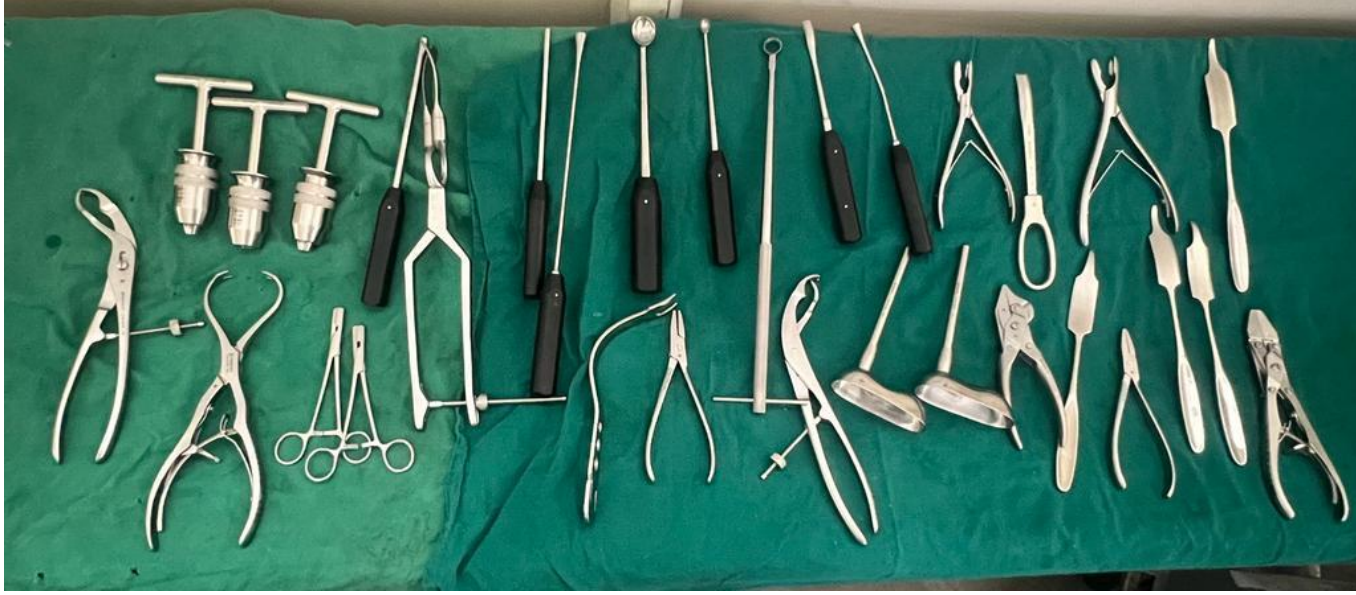Intra op images





## INVENTORY UPGRADATION

With advances in technology, it has become mandatory to upgrade yourself or else, perish. The department is keeping check on such technological innovations and has recently acquired newer instruments and machines to aid us in optimum patient management.



Introducing a new era  
of orthopedic excellence with  
our advanced new set of  
instruments  
designed to optimize surgical  
precision and patient outcomes.

# IN MEMORIAM



**Dr. Suresh G. Ghaisas**

Founder Trustee – MAEER's Group of Institutions

Medical Director

MIMER Medical College

8<sup>th</sup> May 1938 – 18<sup>th</sup> April

2022



Website link

Feedback : [ortho@mitmimer.com](mailto:ortho@mitmimer.com)



<https://www.facebook.com/teamorthomimer>



# THE OSTEON POST

The Quarterly Newsletter of the Department of Orthopaedics,  
MAEER MIT Pune's MIMER Medical College, Talegaon (D)

6<sup>th</sup> Edition,  
1<sup>st</sup> June 2025  
Issue #6

**Issue #5** Editor: Dr Darpan Maheshgauri  
(Professor)

Secretary: Dr. Shubham Chaudhari (Junior Resident)  
Dr. Animesh Gunjal (Junior Resident)

Contributors: Entire department


*It gives us immense pleasure to release the second volume of the Newsletter of Department of Orthopaedics, MIMER Medical College - **The OSTEON**. It is aimed to serve as a platform for all the students and faculty to share their experiences and opinions related to various aspects of Orthopaedics. It will also be a mean to showcase the various happenings in the department which may not necessarily be of only clinical and academic nature.*

*The contributors can share their and that of their colleagues, various extracurricular events, personal achievements, interesting events, artistic compositions etc. It will also be a source to get updated about the important news and significant happenings in the field of Orthopaedics, in and around the region. We hope that it will interest readers and add new dimensions to their thought process.*

*I, on the behalf of Department of Orthopaedics, offer my best wishes to the entire editorial team.*

**Dr Santosh Borkar**

Professor & Head, Department  
of Orthopaedics



## TEAM ORTHO MIMER

|  |   |
|--|---|
| Dr Darpan Maheshgauri (Professor and Medical Superintendent) | Dr Animesh Gunjal (Junior Resident)     |
| Dr Santosh Borkar (Professor and Head of department)         | Dr Aditya Harip (Junior Resident)       |
| Dr Prasanth Kamath (Professor and Head of Unit III)          | Dr Vipul Pise (Junior Resident)         |
| Dr Shivraj Konde (Professor)                                 | Dr Shubham Sanap (Junior Resident)      |
| Dr Manas Pusalkar (Associate Professor)                      | Dr Kairav Purohit (Junior Resident)     |
| Dr Rajeev Munde (Assistant Professor)                        | Dr Govind Tidke (Junior Resident)       |
| Dr Ashwinkumar Madavi (Assistant Professor)                  | Dr Rhythm Tahilramney (Junior Resident) |
| Dr Pranay Kondewar (Senior Resident)                         | Dr Shubham Chaudhari (Junior Resident)  |
| Dr Suraj Doshi (Senior Resident)                             | Dr Jayesh Shirsat (Junior Resident)     |
| Dr Ashutosh Jadav (Senior Resident)                          | Dr. Bhargav Sutar (Junior Resident)     |
|  | Dr. Sameed Ahmed (Junior Resident)      |
|  | Dr Bhushan Adhari (Junior Resident)     |

## Batch 2024



1. Name: Dr Ojas Hiwale
2. Native: Buldhana
3. UG college: MGM Ch. Sambhajinagar
4. Hobbies, co curriculars swimming, sketching.



1. Name :Jay Ganeshrao kadam
2. Native : Washim
3. UG college : IGGMC Nagpur
3. Hobbies, curriculars etcBasketball,Football



1. Name : Dr. Hemant Ashok Patil
2. Native : Malkapur
3. UG college : JNMC Wardha.
3. Hobbies, co curriculars etc. : basketball and volleyball



1. Name :Dr Khan Sadeque
2. Native : Parbhani
3. UG college : Gmc Latur
4. Hobbies :Playing football



1. Name : Onkar Anil Chavan
2. Native : Karad, Satara
3. UG college : T. S. Mishra Medical College and Hospital, Lucknow Uttar pradesh
4. Hobbies, co curriculars etc. : Football, table tennis




1. Name :Dr Ankush Nivrattirao Dhage
2. Native : Nanded, Maharashtra
3. UG college : MIMSR medical College, Latur
4. Hobbies :Playing cricket

## Some Interesting Cases

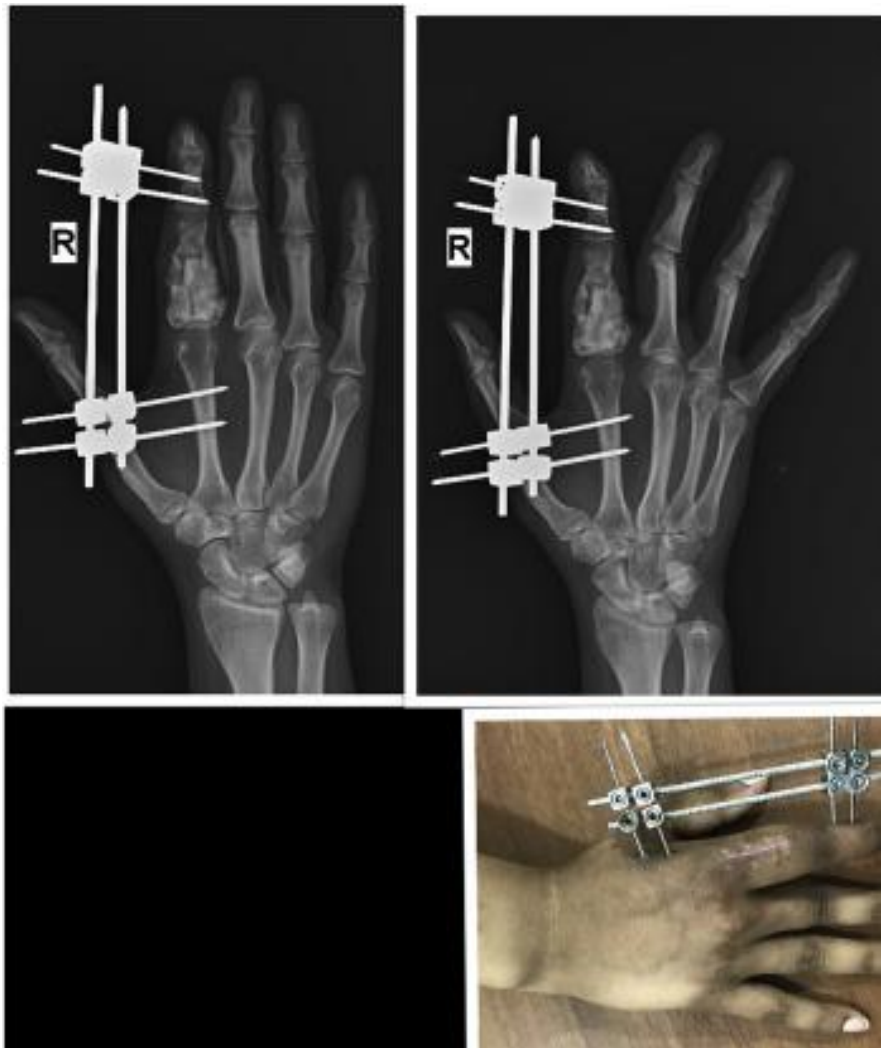In this year, there was a surge in the trauma cases and some interesting fractures and ligamentous injuries presented to the hospital and were real additions to this learning experience

## Dr B.B.Joshi



### *A visionary Hand Surgeon*

Dr. Brij Bhushan Joshi (1928-2009) was a **pioneer in hand surgery**, renowned for his ingenuity and contributions to the field. He was the first in India to earn an M.S. in Orthopaedic Surgery and later became the youngest Chief of Surgery at Lady Irwin Hospital, Delhi<sup>1</sup>. His work at M.G.M. Hospital in Mumbai exposed him to complex hand injuries, inspiring him to develop **sensory skin flaps** to restore tactile function for visually impaired patients. Dr. Joshi also invented **Joshi's External Stabilisation System (JESS)**, a mini-external fixation device used for stabilizing crushed limbs and correcting deformities. His innovative splints, crafted from simple materials, remain widely used today<sup>1</sup>. Through his dedication, he trained a generation of hand surgeons who continue to advance the field



## ALFA FIXATOR HANDS ON WORKSHOP

The Pre-Conference Workshop POSAC-2025, featuring the ALFA Fixator Workshop 2025 (Articulated Lengthening Fixation Apparatus), was organized by Department of Orthopaedics in collaboration with the Pune Orthopaedic Society. The workshop was conducted by Dr. Mangal Parihar, a renowned expert in orthopaedic trauma and limb reconstruction. Dr. Parihar, Dr. Divya Ahuja and team guided participants through hands-on training sessions, sharing cutting-edge methodologies in fracture management and limb lengthening. The event provided an exceptional platform for orthopaedic surgeons and trainees to enhance their skills and exchange knowledge in this evolving field.



# ALL ABOUT CONFERENCES

Dr Santosh Borkar participated as a delegate at 26<sup>th</sup> Annual Conference of Pune Orthopaedic Society 2025 held at Pune



Dr Bhargav Sutar , Dr Rahul Ravariya & Dr Shubham Chaudhari presented paper and poster presentations in Consultant & PG session respectively at POSAC June 2025 held at Hyatt Pune.



## Publications

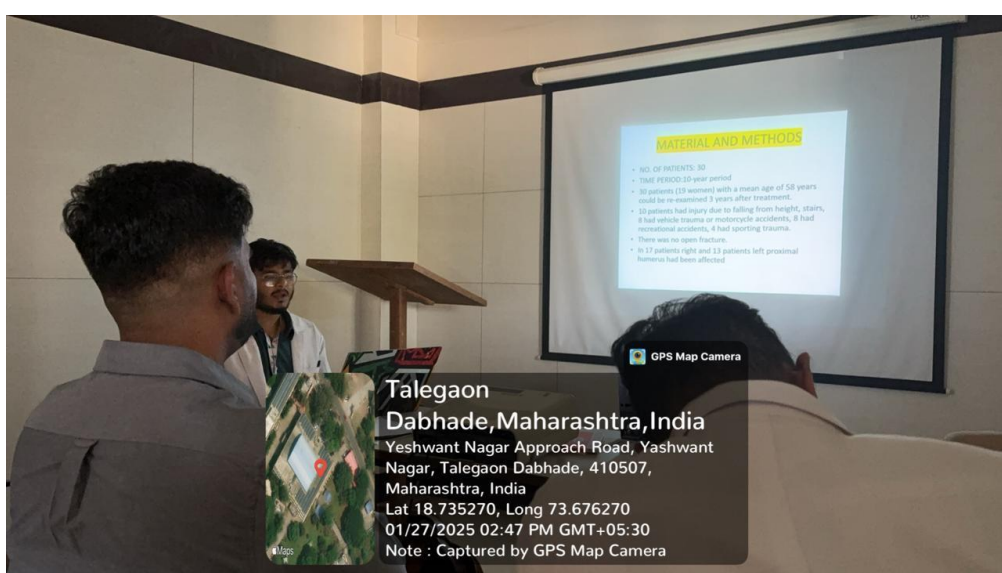Title - Outcomes of displaced Calcaneal fractures operated with an extensile lateral approach of calcaneus

Author - Dr. Santosh Borkar, Dr. Shivraj Konde, Dr. Shrirang Godbole, Dr. Sameed Ahmed, Dr. Rahul Ravariya, Dr. Manas Pusalkar

# Academic PG activities



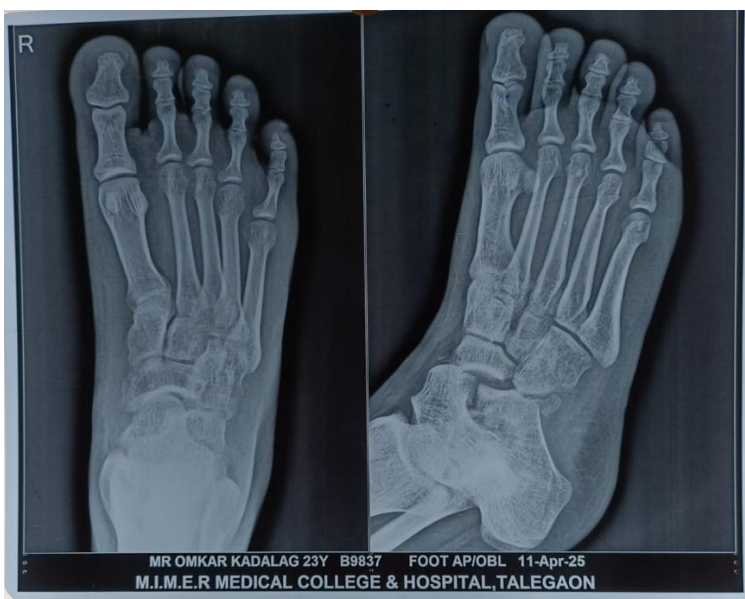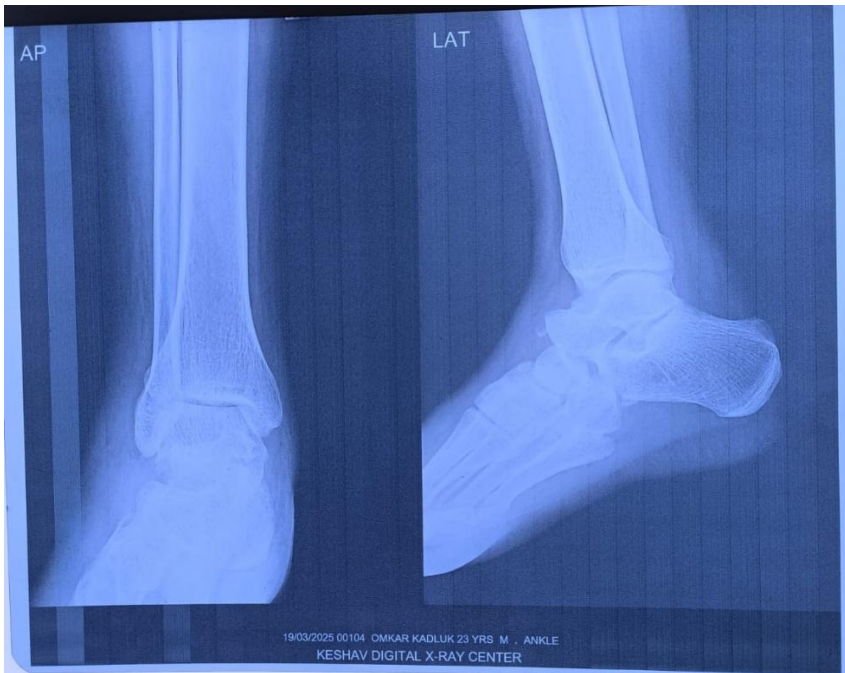
Case presentations !



Journal club

## TRAUMA SERIES

---



A 23 yr old male b/b his relatives with A/H/O fall from bike on 17/03/2025 at around 2:30 pm near chakan.

Patient took primary treatment at Arogyam hospital chakan and xray Right foot was done.

Patient c/o pain and swelling over right foot since incidence

No h/o any other bone or body parts injury

No h/o head injury/ LOC/ ENT bleed/ convulsions

No h/o any known comorbidities

O/E

- 1) Swelling and tenderness present over Right talus region
- 2) ROM Right ankle joint -painful and restricted
- 3) Active toes movements present
- 4) Sensations intact
- 5) Distal pulses palpable
- 6) Capillary refill normal
- 7) Chest/Pelvic compression test negative

Below knee slab given

### Impression :-

Mildly displaced fractures of the antero-inferior portion of calcaneum, posterior portion of navicular and base of 2<sup>nd</sup> metatarsal bones.

Antero-lateral subluxation of talo-navicular joint.

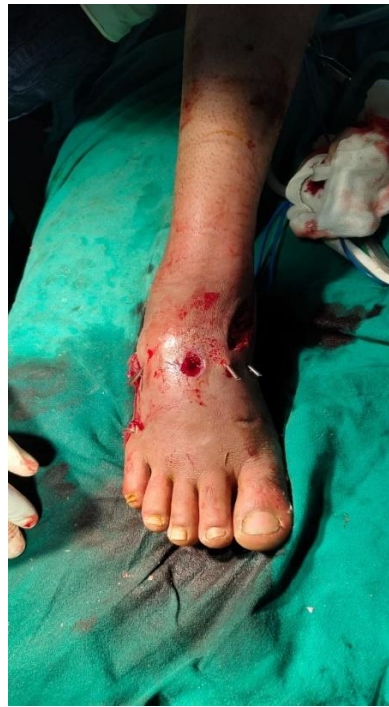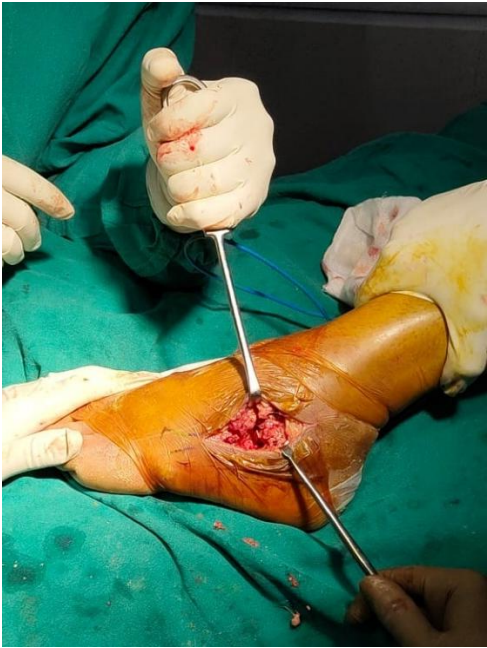Diffuse soft tissue edema surrounding ankle joint.

---

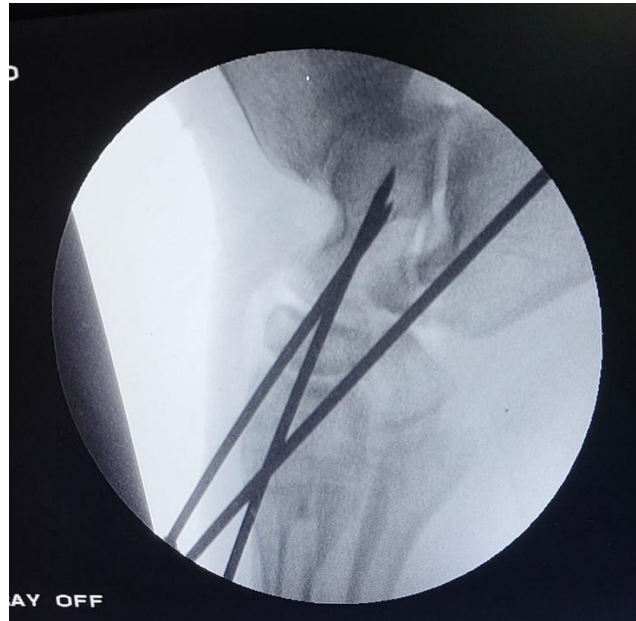
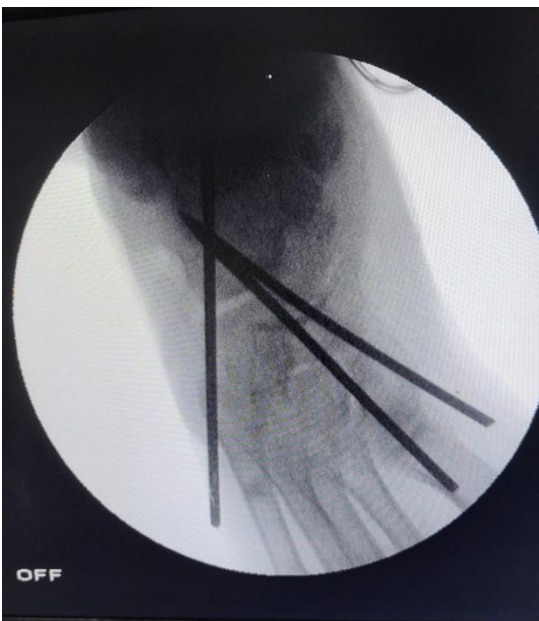
*Patient was operated with Open reduction and internal fixation with K wire*

---

## Intra-op images



## Intra-op x-ray



## Post op x-ray

### Case 2

A 45 year old male Patient was brought to the casualty by relatives with A/H/O RTA while patient was in a 4 wheeler at around 9:00pm on 19/04/25 around Khamgaon Buldhana

Patient took primary treatment in Silver City multi-speciality hospital where patient was admitted on 19/04/25 and was operated for right midshaft femur fracture with CRIF + nailing on 21/04/25. Patient was later discharged on 23/04/25

Patient was then shifted to Atharva multi-speciality Hospital on 23/04/25 where medical management was carried out and later patient was discharged on 28/04/25

H/O head injury/vomiting /LOC present

No H/O any open injury

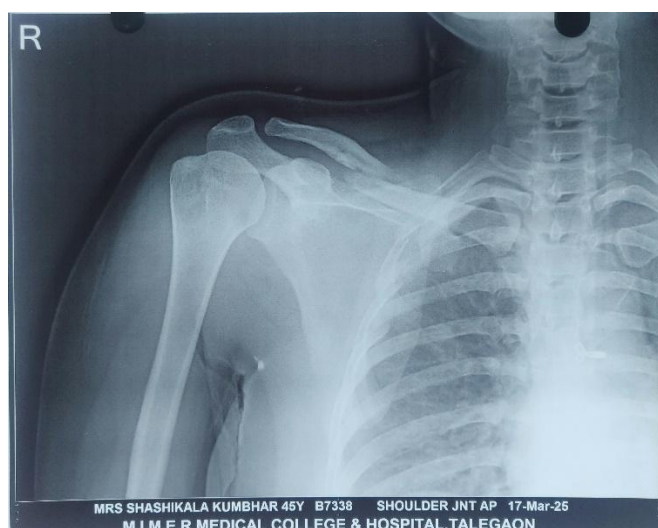
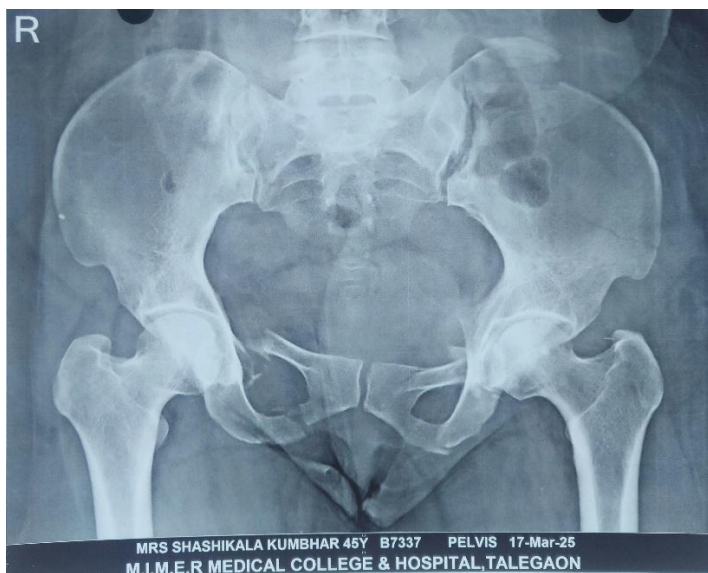
No history of Any known co-morbidities

L/E :

1. Sutured CLW over the forehead and ruptured left pinna
2. No soakage over operative site
3. Swelling and tenderness over the right midshaft clavicle region.
4. ROM right shoulder painful and restricted.
5. Active wrist, finger and thumb movements present.  
Active ankle and toe movements present.
6. Sensation intact
7. Distal pulses palpable
8. Capillary refill normal.
9. Chest compression test positive.
10. Foley's in situ.

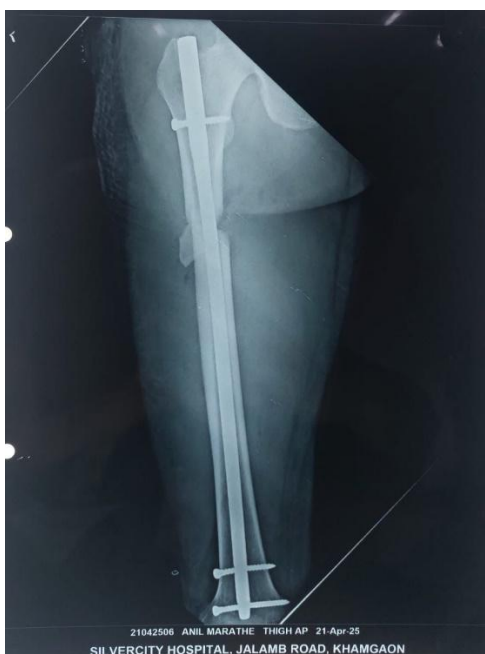Clavicle brace maintained.

Chest binder maintained

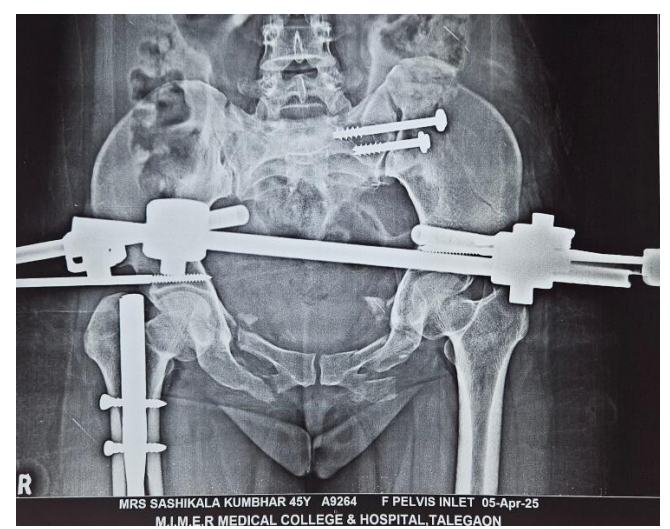
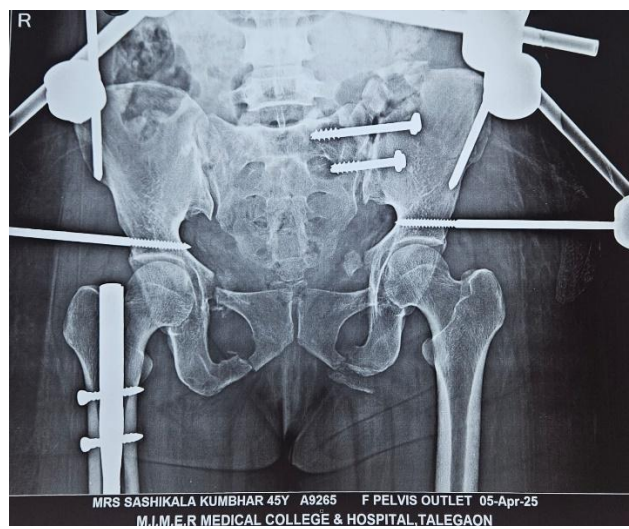
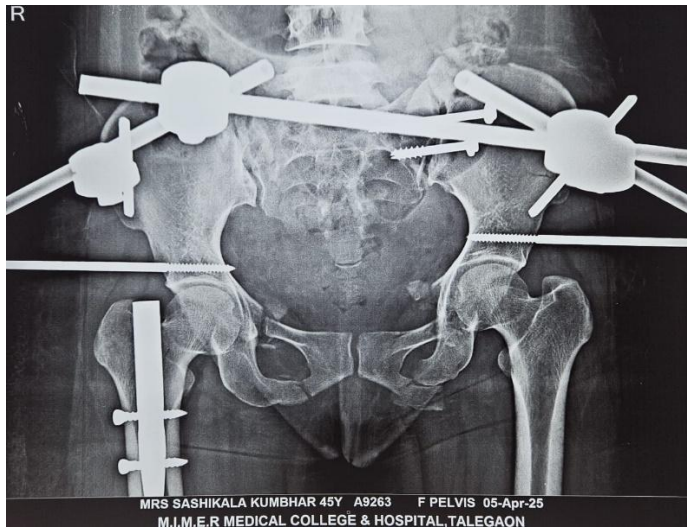


## SURGERY:

Stage 1 surgery was performed for right midshaft femur fracture operated with CRIF + Nailing



Stage 2 surgery was performed for closed reduction with external fixator for pelvis fracture and sacroiliac joint fixation with closed reduction internal fixation + cc screw



# IN MEMORIAM



**Dr. Suresh G. Ghaisas**

Founder Trustee – MAEER's Group of Institutions

Medical Director

MIMER Medical College

8<sup>th</sup> May 1938 – 18<sup>th</sup> April

2022



Website link

Feedback : [ortho@mitmimer.com](mailto:ortho@mitmimer.com)



<https://www.facebook.com/teamorthomimer>



# THE OSTEON POST

The Quarterly Newsletter of the Department of Orthopaedics,  
MAEER MIT Pune's MIMER Medical College, Talegaon (D)

6<sup>th</sup> Edition,  
1<sup>st</sup> Oct 2024  
Issue #7

**Issue #6** Editor: Dr Darpan Maheshgauri  
(Professor)

Secretary: Dr. Animesh Gunjal (Junior Resident)

Contributors: Entire department

*It gives us immense pleasure to release the second volume of the Newsletter of Department of Orthopedics, MIMER Medical College - **The OSTEON**. It is aimed to serve as a platform for all the students and faculty to share their experiences and opinions related to various aspects of Orthopedics. It will also be a mean to showcase the various happenings in the department which may not necessarily be of only clinical and academic nature.*

*The contributors can share their and that of their colleagues, various extracurricular events, personal achievements, interesting events, artistic compositions etc. It will also be a source to get updated about the important news and significant happenings in the field of Orthopedics, in and around the region. We hope that it will interest readers and add new dimensions to their thought process.*

*I, on the behalf of Department of Orthopedics, offer my best wishes to the entire editorial team.*

**Dr Santosh Borkar**

Professor & Head, Department  
of Orthopedics



## TEAM ORTHO MIMER

|  |   |
|--|---|
| Dr Darpan Maheshgauri (Professor and Medical Superintendent) | Dr Animesh Gunjal (Junior Resident)     |
| Dr Santosh Borkar (Professor and Head of department)         | Dr Aditya Harip (Junior Resident)       |
| Dr Prasanth Kamath (Professor and Head of Unit III)          | Dr Vipul Pise (Junior Resident)         |
| Dr Shivraj Konde (Professor)                                 | Dr Shubham Sanap (Junior Resident)      |
| Dr Manas Pusalkar (Associate Professor)                      | Dr Kairav Purohit (Junior Resident)     |
| Dr Rajeev Munde (Assistant Professor)                        | Dr Govind Tidke (Junior Resident)       |
| Dr Ashwinkumar Madavi (Assistant Professor)                  | Dr Rhythm Tahilramney (Junior Resident) |
| Dr Pranay Kondewar (Senior Resident)                         | Dr Shubham Chaudhari (Junior Resident)  |
| Dr Suraj Doshi (Senior Resident)                             | Dr Jayesh Shirsat (Junior Resident)     |
| Dr Ashutosh Jadav (Senior Resident)                          | Dr.Bhargav Sutar(Junior Resident)       |
|  | Dr.Sameed Ahmed(Junior Resident)        |

Dr Bhushan Adhari(Junior Resident)

Dr Ankush Dhage (Junior Resident)

Dr Hemant Patil (Junior Resident)

Dr Jay Kadam (Junior Resident)

Dr Sadique khan (Junior Resident)

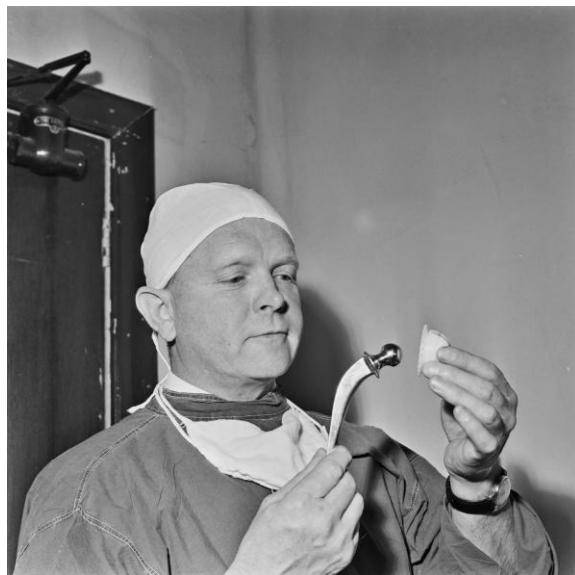Dr Onkar Chavan (Junior Resident)

Dr Ojas Hiwale (Junior Resident)

## Some Interesting Cases

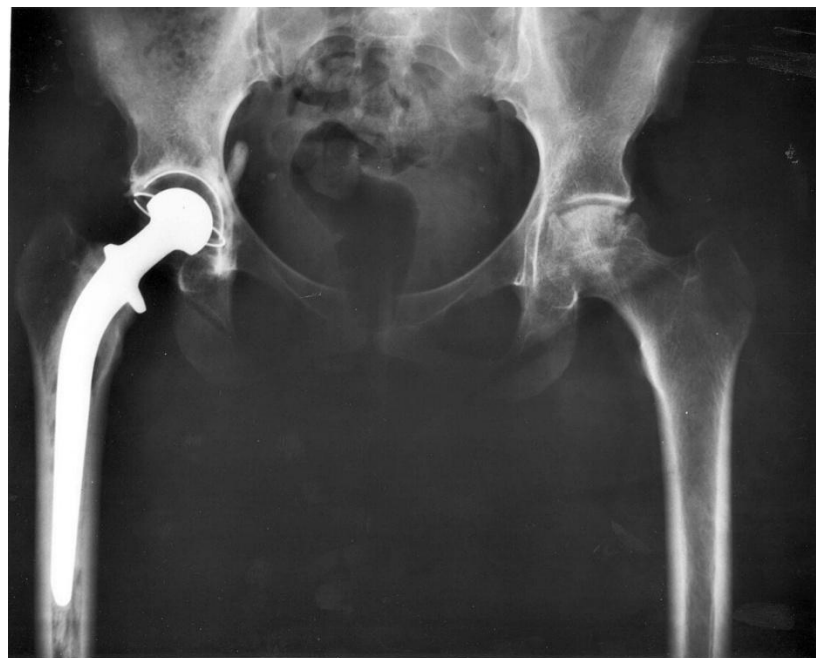In this year, there was a surge in the trauma cases and some interesting fractures and ligamentous injuries presented to the hospital and were real additions to this learning experience

## Dr John Charnley



### Total Hip Replacement Pioneer:

*Sir John Charnley (1911–1982) was a towering figure in orthopedic surgery, best known for revolutionizing the treatment of hip arthritis through the development of total hip arthroplasty (THA). Charnley introduced the low-friction arthroplasty concept, using a metal femoral stem, polyethylene acetabular cup, and acrylic bone cement—a combination that remains foundational in modern THA. Biomechanical Insight: He emphasized bony compression in joint arthrodesis, particularly for the knee, ankle, and shoulder.*



## Workshop on Open Bony Injuries and External Fixation

A presentation on Open Bony Injuries and External Fixation was organized for the students, followed by a dry bone model workshop in the Skill Lab. The session aimed to enhance clinical understanding and provide hands-on experience in fracture management techniques. The event was held at 1:30 PM in the Skill Lab, MIMER medical college , Talegaon Dabhade Pune.





## ALL ABOUT CONFERENCES

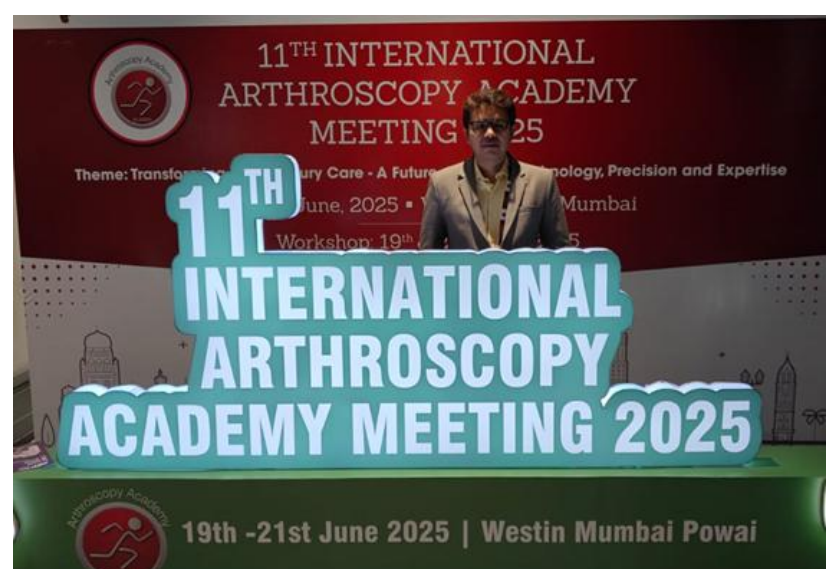Dr Rajiv Munde was invited as faculty in Meniscus Repair Workshop at IASCON 2025 (22nd Annual Conference of the Indian Arthroscopy Society), on September 26–28, 2025, at the Taj Cidade De Goa Horizon in Goa.



Dr Shubham Chaudhari , Dr Rahul Ravariya , Dr Jayesh Shirsat, Dr Sameed Ahmed & Dr Animesh Gunjal attended as delegate in 8<sup>th</sup> Dr Steve Rochia memorial stimulus Pg training course held at Sancheti Hospital, Pune in August 2025.



Dr Rajiv Munde was invited as faculty for 11th International Arthroscopy Academy Conference at Westin Mumbai Powai on 19-21st June 2025 .



Dr Santosh Borkar ( Faculty) and Dr Aditya Harip attended Pune Pediatric Orthopaedics course 2025 held at KEM Hospital Pune on 10<sup>th</sup> August 2025 .



Dr Santosh Borkar was awarded certificate of excellence in appreciation of meritorious performance in singing – Navratotsav conducted as part of cultural/sports in events by Rajgurunagar Medical practitioners Association in the year 2024-2025.

Dr Suraj Doshi took lecture on First Aid in Industry Trauma and CPR for SS Pitkar Industry Employees on 19/9/2025.



# Academic PG activities



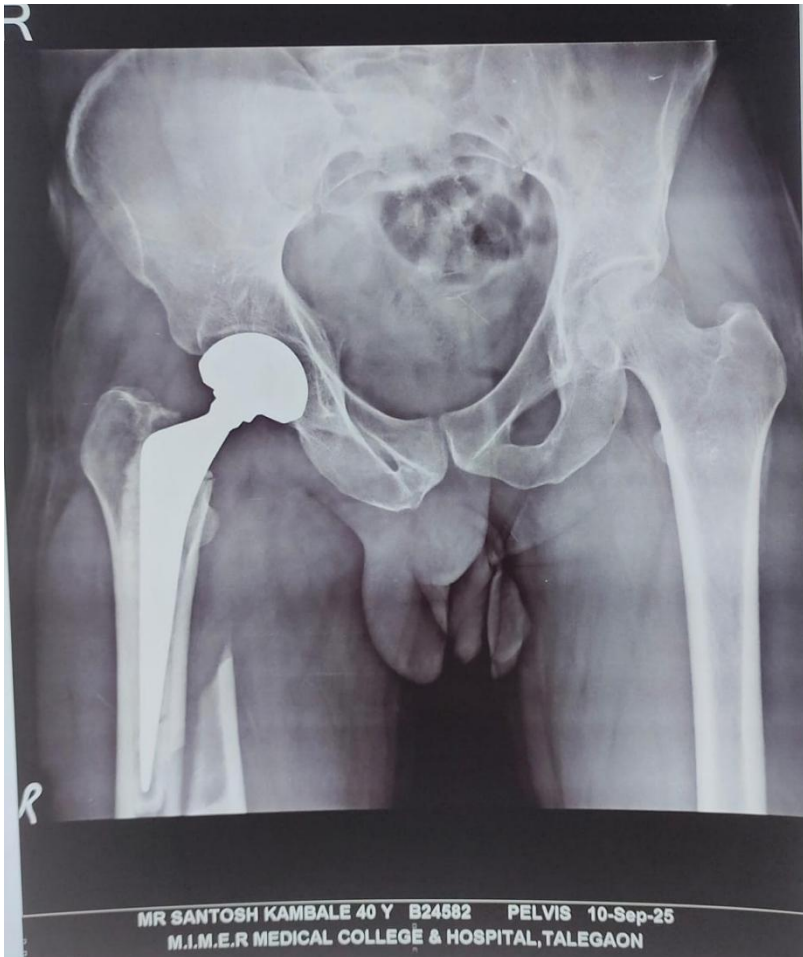Case  
presentations !



Journal club



## TRAUMA SERIES



A 40 years old male patient was brought to casualty by relatives with A/H/O slip and fall from ladder(8 ft) while working at his workplace in aaryan hotel ,vadgaon phata on 10/9/25 at around 1:30pm

Patient complaints of pain and swelling over right wrist and right hip and thigh region since then

No history of head injury/LOC/ ENT bleed/nausea/vomiting

No history of any known co morbidities

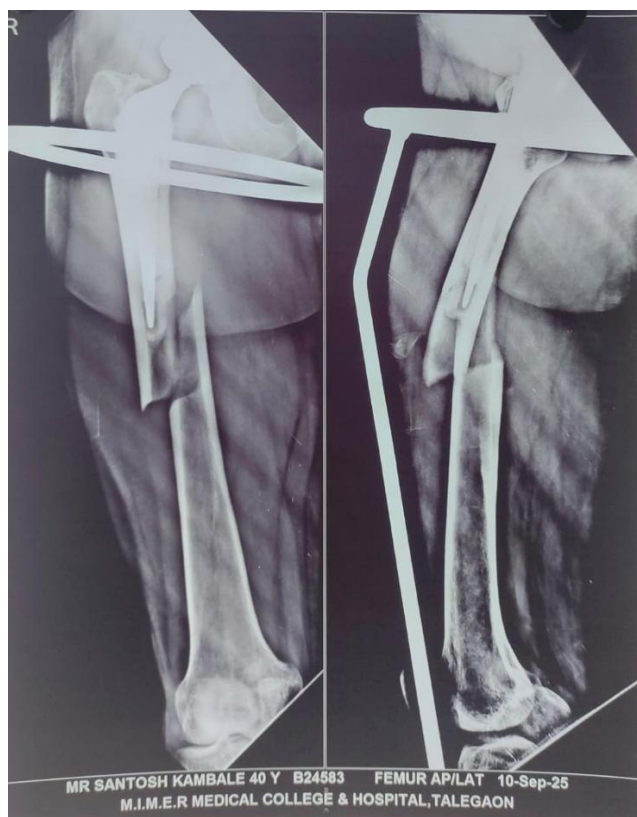
No history of any open injury

Patient is operated case of right neck of femur fracture operated with cemented bipolar hemiarthroplasty operated at YCM hospital on 3/6/25.

On examination:

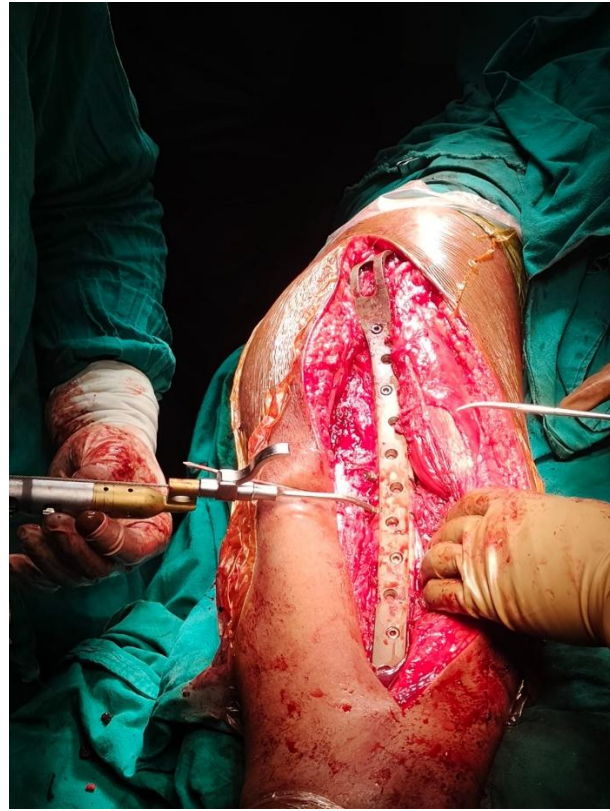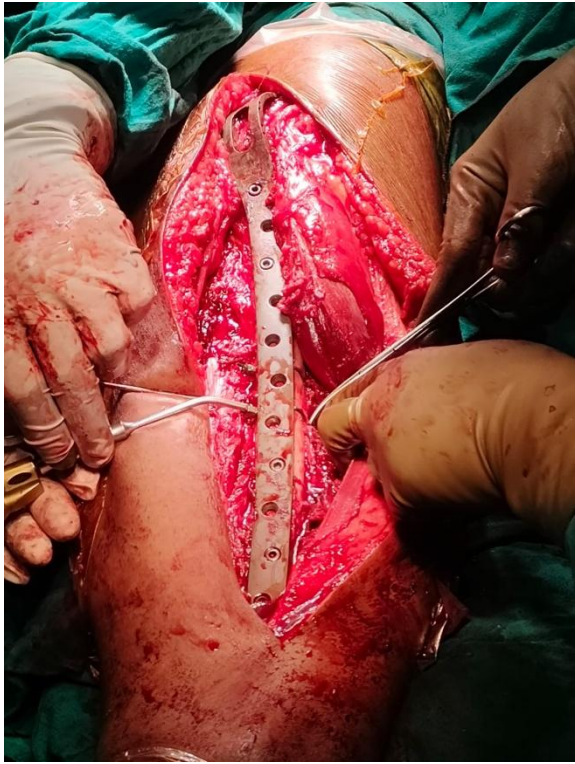
1. Tenderness present over right wrist region and right proximal and midshaft femur region
2. ROM at right wrist joint - possible but terminally painful  
ROM at right hip joint - painful and restricted
3. Active SLR not possible on right side
4. Active finger, thumb ,ankle and toe movements present
5. Sensations intact
6. Distal pulse palpable
7. Capillary refill normal
8. No spinal/ calcaneum tenderness present
9. Chest compression test -negative

Thomas splint given

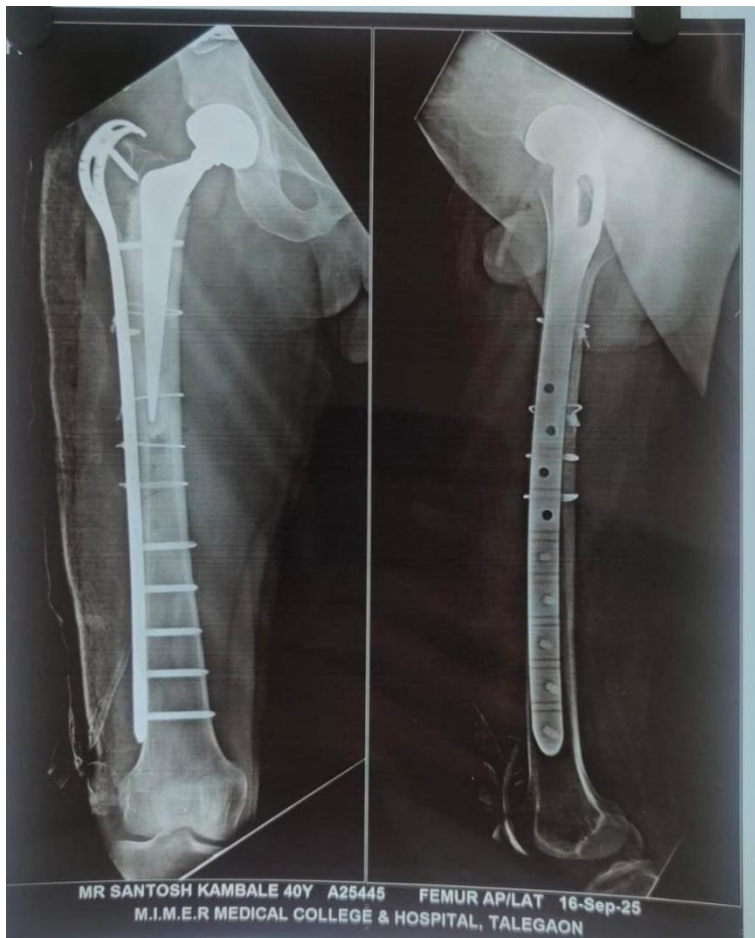

*Patient was operated with Open reduction and internal fixation with plating (titanium) with cables*

Intra-op images



Post op x-ray



## Case 2

23 year old male came to OPD with complaints of pain over right thigh region and right knee region with difficulty while walking with abnormal gait since 40 days.

He is an operated case of compound type 3 A fracture distal 1/3 rd femur of right side + fracture midshaft Tibia of right side o/w wound debridement + CR + external fixator application for tibia and femur fracture on 19/10/2024 at Dr. BSTR hospital.

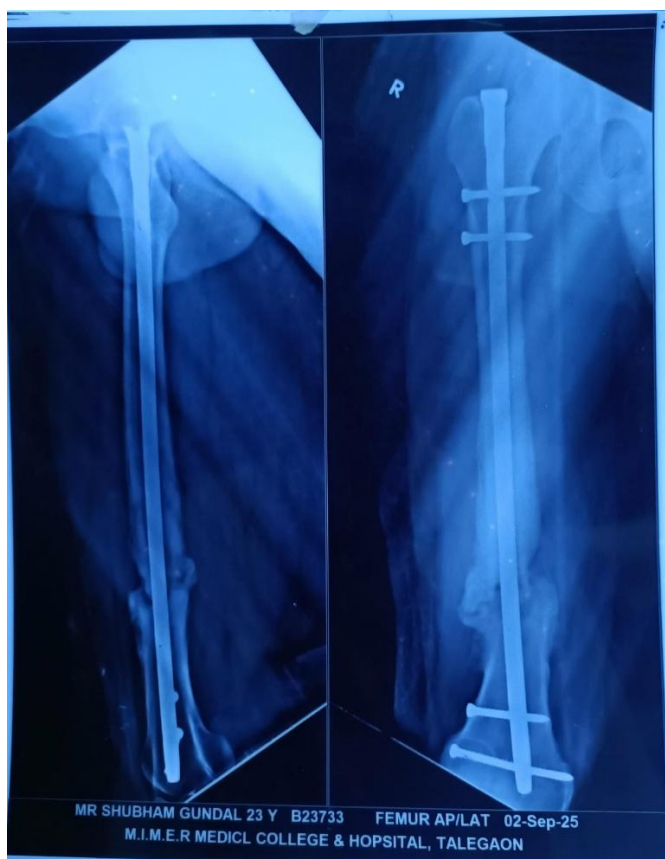It was followed up by definitive fixation by debridement + external fixator removal + CRIF + Nailing for tibia and femur fracture on 24/10/24 at Dr. BSTR hospital.

No history of recent fall/trauma

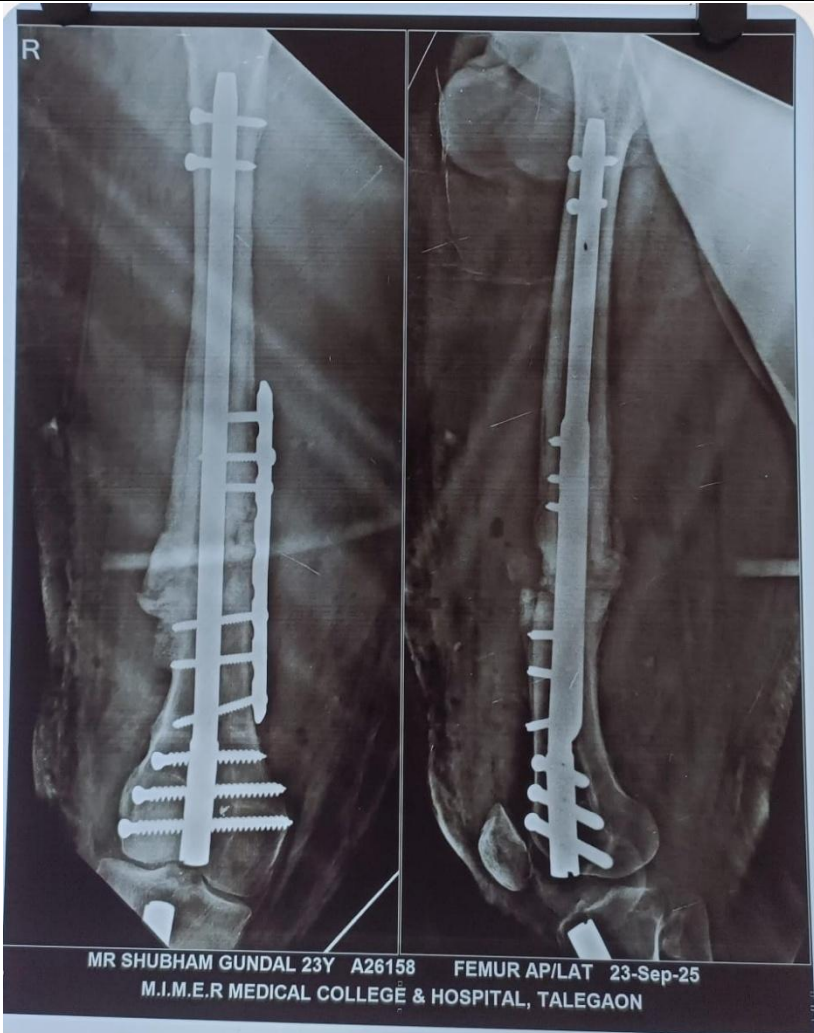
No history of HTN /DM/ Asthma /TB

Local Examination:

- 1) Visible valgus deformity seen over right knee
- 2) Scar Site Healthy
- 3) Tenderness present over right midshaft femur region and medial aspect of right knee joint
- 4) ROM at right knee joint possible but terminally painful
- ROM at right hip joint full range and painless
- 5) Active ankle and toe movements present
- 6) Sensations Intact
- 7) Distal pulses palpable
- 8) Capillary refill normal



**SURGERY: IMPLANT REMOVAL FOR FEMUR NAIL AND CRIF + RETROGRADE NAILING AND ORIF + PLATING + BONE GRAFTING**



# IN MEMORIAM



**Dr. Suresh G. Ghaisas**

Founder Trustee – MAEER's Group of Institutions

Medical Director

MIMER Medical College

8<sup>th</sup> May 1938 – 18<sup>th</sup> April

2022



Website link

Feedback : [ortho@mitmimer.com](mailto:ortho@mitmimer.com)



<https://www.facebook.com/teamorthomimer>